

Journal of Nephrologist



A unique finding of normal aldosterone level in Bartter's syndrome

Rupesh Raina^{1*}, Tushar Chaturvedi², Shyam Polaconda², Amrita Siri Mukunda², Sidharth Kumar Sethi³, Vinod Krishnappa²

¹Division of Nephrology, Cleveland Clinic Akron General, Akron, Ohio, USA

²Cleveland Clinic Akron General/Akron Nephrology Associates, Akron, Ohio, USA

³Kidney Institute, Medanta, The Medicity Hospital, Gurgaon, Haryana, India

ARTICLE INFO

Article type:
Case Report

Article history:
Received: 18 March 2017
Accepted: 10 June 2017
Published online: 27 June 2017
DOI: 10.15171/jnp.2017.59

Keywords:
Bartter's syndrome
Hypokalemia
Renal tubular acidosis
Hypermagnesuria
Normal aldosterone levels

ABSTRACT

Background: Bartter's syndrome is a rare autosomal recessive renal tubular disorder characterized by hypokalemia, hypochloremia, metabolic alkalosis, hyperreninemia and hyperaldosteronemia with normotension. Bartter syndrome has five types; type 1 (mutation in sodium/potassium chloride transporter), type 2 (mutation in voltage gated potassium channel), type 3 (mutation on chromosome 1 that encodes Barttin and makes only kidney-specific chloride channel B non-functional), type 4 (mutation in *BSND* gene encoding Barttin and makes both kidney-specific chloride channels A & B non-functional) and type 5 (L125P gain in function mutation in calcium-sensing receptor).

Case Presentation: A 28-year-old male was hospitalized for evaluation of nausea, vomiting, generalized weakness and persistent chronic hypokalemia. Bartter's syndrome was suspected based on clinical and laboratory evidence, however serum aldosterone level was normal. Further genetic testing confirmed the diagnosis of Bartter's syndrome type 3.

Conclusions: We report a case of Bartter's syndrome type 3 with a unique finding of normal aldosterone level.

Implication for health policy/practice/research/medical education:

Bartter's syndrome with normal aldosterone level is a rare finding. The approach to such patients needs to be further explored. The treatment of Bartter's is long term potassium replacement, intravenous hydration and prostaglandin synthase inhibitors like indomethacin and ketoprofen. COX-2 inhibitors such as rofecoxib can be substituted to avoid long-term side effects and in patients refractory to indomethacin.

Please cite this paper as: Raina R, Chaturvedi T, Polaconda S, Mukunda AS, Sethi SK, Krishnappa V. A unique finding of normal aldosterone level in Bartter's syndrome. J Nephrologist. 2017;6(4):359-362. DOI: 10.15171/jnp.2017.59.

1. Introduction

Bartter's syndrome is a rare renal tubular disorder that is autosomal recessive in nature (1). The incidence of Bartter's syndrome is 1.2 per million people (2). Bartter et al first described this disease in 1962 and characterized by salt wasting, hypochloremia, hypokalemia, metabolic alkalosis, and frequently associated with recurrent dehydration and failure to thrive (3,4). Besides fluid and electrolyte abnormality, hyperreninemia and hyperaldosteronemia with normal blood pressures are seen in patients with Bartter's syndrome (5,6). The underlying pathology is mutation of genes encoding transport proteins in the thick ascending loop of

Henle that decreases reabsorption of sodium in conjunction with increased secretion of potassium and hydrogen in to the urine, resulting in electrolyte and hormonal imbalance (7). We report a case of Bartter's syndrome with an unusual finding of a normal aldosterone level and absence of metabolic alkalosis.

2. Case Presentation

A 28-year-old Caucasian male presented to emergency room with history of generalized weakness, nausea and vomiting. Also, history of craving for salt, poor appetite and nocturia noted in the past. He was diagnosed to have distal renal tubular acidosis (distal

*Corresponding author: Rupesh Raina, Email: rrain@chmca.org, raina@akronnephrology.com

Table 1. Blood laboratory results

Date	Na ⁺	K ⁺	HCO ₃	BUN	Cr	Ca ²⁺	Mg ²⁺	Hb	Alb
11/20/16	137	3.8	26	13	0.99	9.6	2.2		4.7
09/27/16	135	4.3	25	9	1.21	9.0	2	10.9	
07/26/16	136	1.6	24	19	1.06	9.7	2.1		5.0
07/10/16	135	1.8	25	12	1.18	8.9	2.6	12.6	
02/05/16	136	2.1	26	9	1.05	9.0	2.5	13.2	
09/18/15	134	2.0	24	15	1.00	9.8	1.9	10.0	4.9
08/17/15	139	3.1	25	13	0.89	9.2	2.2	10.2	4.4
03/06/15	134	2.6	24	16	0.99	9.8	2.4		4.6
03/05/15	134	2.9	22	14	0.92	8.9	1.5	9.2	
10/22/14	138	2.3	29	9	0.92	8.5			3.7
10/21/14	136	1.7	24	16	1.16	9.8	1.2	10	4.1

Na, sodium (mEq/L); K, potassium (mEq/L); HCO₃, bicarbonate (mEq/L); BUN, blood urea nitrogen (mg/dL); Cr, creatinine (mg/dL); Ca, calcium (mg/dL); Mg, magnesium (mEq/L); Hb, hemoglobin (g/dL); Alb, albumin (g/dL).

RTA or type 1 RTA) previously and was on bicarbonate therapy. His past medical history is significant for chronic kidney disease (CKD) stage I, chronic hypokalemia and right bundle branch block since the age of 2 years apart from history of hypophosphatemia, hypomagnesemia, pneumothorax and depression. There was a history of multiple hospitalizations for hypokalemia (lowest noted was 0.9 mEq/L) and recurrent abdominal pain, and was on potassium supplementation. His serum electrolytes and renal functions from the last two years are tabulated below in Table 1, and electrolyte trends over time is depicted in Figure 1. He was not evaluated by a nephrologist in the past and family history was significant for hypokalemia (sister). He smokes cigarettes and marijuana.

On physical examination, he was a tall, thin and frail person with a body mass index (BMI) of 15.65 kg/m². His blood pressure was 100/60 mm Hg and abdominal examination was benign. Initial lab work up in the emergency room showed potassium 1.8 mEq/L (normal 3.5-5 mEq/L), spot urine potassium to creatinine ratio >1.5 mEq/mmol creatinine (indicates renal potassium wasting) and bicarbonate was 23 mEq/L (normal 22-28 mEq/L). There was no evidence of metabolic alkalosis in the setting of continuous vomiting. He was given intravenous potassium chloride infusion and 0.9% normal saline. We suspected Bartter's syndrome clinically and further evaluation revealed high renin but normal aldosterone level. A 24-hour urine electrolytes showed sodium and potassium wasting, hypermagnesuria and hypercalciuria. A trans-tubular potassium gradient (TTKG) was high indicating renal potassium loss. A substantially lower value (<3) reflects an attempt to conserve potassium in patients with hypokalemia secondary to extra renal losses or an intracellular shift due to diuretic abuse. Genetic testing was consistent with Bartter's syndrome type 3.

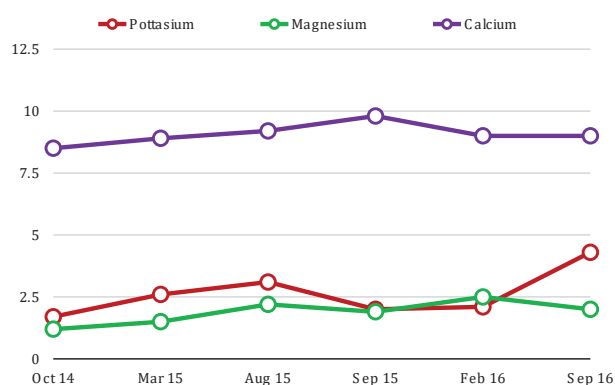


Figure 1. Blood electrolyte trends over time. Unit of measurements: Potassium, mEq/L; Magnesium, mEq/L; Calcium, mg/dL.

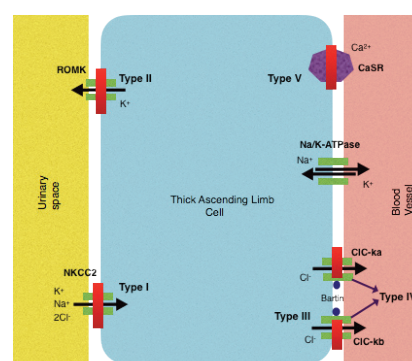


Figure 2. Illustration of genetic mutations and underlying channel defects in different types of Bartter's syndrome. ROMK - renal outer medullary potassium channel gene, NKCC2 – sodium-potassium-chloride co-transporter gene, ClCka - kidney-specific chloride channel A, ClCkb - kidney-specific chloride channel B, CaSR – calcium sensing receptor.

He was started on spironolactone 100 mg oral twice a day along with amiloride to prevent renal potassium loss. In addition, he was also given indomethacin 50

mg oral once daily to inhibit prostaglandin synthesis and continued oral potassium 40 mEq every 6 hours. His condition improved remarkably and serum potassium normalized. He was discharged home with a plan for intravenous potassium twice a week at an infusion clinic and replenishing phosphate, and was advised to follow up in 2 months.

3. Discussion

Bartter's syndrome type 1 is caused by frame shift, nonsense and missense mutation in *NKCC2* gene (sodium-potassium-chloride co-transporter gene) on chromosome 15 that encodes Na-K-2Cl cotransporter in the thick ascending loop of Henle (8) (Figure 2). Bartter's syndrome type 2 is due to a mutation in *ROMK* gene (renal outer medullary potassium channel gene) that encodes ATP sensitive potassium channels disrupting the regulation of potassium in the tubular lumen (9). Bartter syndrome type 3 is a salt losing tubulopathy due to a mutation on chromosome 1 that encodes for Barttin and renders only kidney-specific chloride channel B (CICKB) non-functional (10). Barttin is located in the ascending loop of Henle and the marginal cells of the inner ear, and regulates the chloride channels CICKA and CICKB. Thus mutation in the *BSND* gene encoding Barttin results in Bartter's type 4 which is characterized by both sensorineural deafness and severe salt losing phenotype since both the CICKA and the CICKB are affected, as opposed to Bartter's type 3 where only CICKB is affected (10-13). Type 5 Bartter's syndrome occurs as a result of *L125P* gain in function mutation in calcium-sensing receptor (CaSR) in the cortical thick ascending loop of Henle reducing NaCl reabsorption causing hypokalemia, hypocalcemia, hypercalciuria and secondary hyperaldosteronism (14).

Bartter's syndrome is characterized by hypokalemia, hypochloremia, hyperreninemia and hyperaldosteronemia with normotension. Antenatal or neonatal Bartter's syndrome (type 1 and type 2) usually manifests as polyhydramnios in the third trimester of pregnancy and presents with polyuria, polydipsia, hypercalciuria and nephrocalcinosis during infancy (4). Type 3 or classic Bartter's syndrome is commonly diagnosed at school age or later although symptoms may have been present during infancy and early childhood (15). Bartter's syndrome causes plasma volume contraction resulting in the compensatory stimulation of the renin-angiotensin-aldosterone-system (RAAS) resulting in increased aldosterone levels. Our patient manifested in a similar manner except for normal aldosterone level. His clinical features and laboratory findings were suggestive of either Bartter's syndrome or Gitelman

syndrome, however, early onset of disease at two years of age, growth abnormalities and cachexia support a diagnosis of Bartter's syndrome. His normal aldosterone and bicarbonate levels are perplexing but the metabolic alkalosis could be masked by his recurrent vomiting which may be cyclical vomiting syndrome in the setting of marijuana use. Normal aldosterone level in Bartter's syndrome is very uncommon and similar finding was reported by Huque et al in a three-and-a-half-month old infant (5).

The current treatment for Bartter's syndrome involves long term potassium replacement, intravenous hydration and prostaglandin synthase inhibitors like indomethacin and ketoprofen (16). Due to the adverse effects of long term medication use, Cox-2 inhibitors like rofecoxib can be substituted (15,17). Rofecoxib can also be administered in patients, refractory to indomethacin treatment (18). A study by Mendonça et al described the use of aliskiren, a direct renin inhibitor, to counteract hyperreninemia in Bartter's syndrome there by reducing the amount of potassium required to be administered therapeutically (19). ACE inhibitors like enalapril have also been described to improve the potassium regulation in Bartter's syndrome (20).

4. Conclusions

Bartter's syndrome with normal aldosterone level is a rare finding and there is scant amount of literature describing this unique association. To the best of our knowledge there has been no such adult case reported. The approach to such patients needs to be further explored.

Authors' contribution

Authors contributed to the manuscript equally.

Conflicts of interest

The authors declare that they have no conflicting interest.

Ethical considerations

Informed consent was obtained from the patient for publication as a case report.

Funding/support

None.

References

1. Bhat YR, Vinayaka G, Sreelakshmi K. Antenatal bartter syndrome: a review. *Int J Pediatr.* 2012;2012:857136. doi: 10.1155/2012/857136.
2. Rudin A. Bartter's syndrome. A review of 28 patients followed for 10 years. *Acta Med Scand.*

- 1988;224(2):165-71.
3. Bartter FC, Pronove P, Gill J, MacCardle RC. Hyperplasia of the juxtaglomerular complex with hyperaldosteronism and hypokalemic alkalosis. A new syndrome. *Am J Med.* 1962; 33:811-28.
 4. Özdemir ÖM, Çıralı C, Yılmaz Ağladioğlu S, Evrengül H, Tepeli E, Ergin H. Neonatal Bartter syndrome with cholelithiasis and hydrocephalus: Rare The association. *Pediatr Int.* 2016;58(9):912-5. doi: 10.1111/ped.12999.
 5. Huque SS, Rahman MH, Khatun S. Bartter syndrome with normal aldosterone level: an unusual presentation. *Mymensingh Med J.* 2016;25(2):366-9.
 6. Hussain S. Neonatal Bartter syndrome in association with congenital adrenal hyperplasia in a neonate - a rare combination. *J Pak Med Assoc.* 2016;66(5):612-4.
 7. Heilberg IP, Tótolı C, Calado JT. Adult presentation of Bartter syndrome type IV with erythrocytosis. *Einstein (Sao Paulo).* 2015;13(4):604-6. doi: 10.1590/S1679-45082015RC3013.
 8. Simon DB, Karet FE, Hamdan JM, DiPietro A, Sanjad SA, Lifton RP. Bartter's syndrome, hypokalaemic alkalosis with hypercalciuria, is caused by mutations in the Na-K-2Cl cotransporter NKCC2. *Nat Genet.* 1996;13(2):183-8.
 9. Mutations in the gene encoding the inwardly-rectifying renal potassium channel, ROMK, cause the antenatal variant of Bartter syndrome: evidence for genetic heterogeneity. International Collaborative Study Group for Bartter-like Syndromes. *Hum Mol Genet.* 1997;6(1):17-26.
 10. Krämer BK, Bergler T, Stoelcker B, Waldegger S. Mechanisms of disease: the kidney-specific chloride channels CICKA and CICKB, the Barttin subunit, and their clinical relevance. *Nat Clin Pract Nephrol.* 2008;4(1):38-46.
 11. Estévez R, Boettger T, Stein V, Birkenhäger R, Otto E, Hildebrandt F, et al. Barttin is a Cl⁻ channel beta-subunit crucial for renal Cl⁻ reabsorption and inner ear K⁺ secretion. *Nature.* 2001;414(6863):558-61.
 12. Janssen AG, Scholl U, Domezeyer C, Nothmann D, Leinenweber A, Fahlke C. Disease-causing dysfunctions of barttin in Bartter syndrome type IV. *J Am Soc Nephrol.* 2009;20(1):145-53. doi: 10.1681/ASN.2008010102.
 13. Birkenhäger R, Otto E, Schürmann MJ, Vollmer M, Ruf EM, Maier-Lutz I, et al. Mutation of BSND causes Bartter syndrome with sensorineural deafness and kidney failure. *Nat Genet.* 2001;29(3):310-4.
 14. Vargas-Poussou R, Huang C, Hulin P, Houillier P, Jeunemaître X, Paillard M, et al. Functional characterization of a calcium-sensing receptor mutation in severe autosomal dominant hypocalcemia with a Bartter-like syndrome. *J Am Soc Nephrol.* 2002;13(9):2259-66.
 15. Vaisbich MH, Fujimura MD, Koch VH. Bartter syndrome: benefits and side effects of long-term treatment. *Pediatr Nephrol.* 2004;19(8):858-63.
 16. Littlewood JM, Lee MR, Meadow SR. Treatment of Bartter's syndrome in early childhood with prostaglandin synthetase inhibitors. *Arch Dis Child.* 1978;53(1):43-8.
 17. Kleta R, Basoglu C, Kuwertz-Bröking E. New treatment options for Bartter's syndrome. *N Engl J Med.* 2000;343(9):661-2.
 18. Haas NA, Nossal R, Schneider CH, Lewin MA, Ocker V, Holder M, et al. Successful management of an extreme example of neonatal hyperprostaglandin-E syndrome (Bartter's syndrome) with the new cyclooxygenase-2 inhibitor rofecoxib. *Pediatr Crit Care Med.* 2003;4(2):249-51.
 19. Mendonça M, Pinheiro A, Castro I. [Bartter syndrome: a new therapeutic approach]. *Acta Med Port.* 2011 ;24 Suppl 3:671-4.
 20. Hené RJ, Koomans HA, Dorhout Mees EJ, vd Stolpe A, Verhoef GE, Boer P. Correction of hypokalemia in Bartter's syndrome by enalapril. *Am J Kidney Dis.* 1987;9(3):200-5.

Copyright © 2017 The Author(s); Published by Society of Diabetic Nephropathy Prevention. This is an open-access article distributed under the terms of the Creative Commons Attribution License (<http://creativecommons.org/licenses/by/4.0>), which permits unrestricted use, distribution, and reproduction in any medium, provided the original work is properly cited.