

Journal of Nephropathology



Steroid-resistant minimal change disease with ballooned podocytes

Francesco Fortarezza^{1*}, Maria Grazia Fiore¹, Michele Rossini², Domenico Piscitelli¹, Loreto Gesualdo², Leonardo Resta¹, Roberta Rossi¹

¹Department of Emergency and Organ Transplantation, Pathology Division, Medical School, University of Bari, Bari, Italy

²Department of Emergency and Organ Transplantation, Nephrology Division, Medical School, University of Bari, Bari, Italy

ARTICLE INFO

Article type:
Photonephropathol

Article history:
Received: 2 March 2017
Accepted: 4 September 2017
Published online: 27 September 2017

Keywords:
Minimal change disease
CMV infection
ACTN4 gene

Implication for health policy/practice/research/medical education:

Minimal change disease (MCD) is a disorder affecting the kidneys which causes a nephrotic syndrome. The pathogenesis is unclear and genetic, immunological factors and infections have been studied as a possible trigger. We describe a case of steroid-resistant MCD with an unusual pattern of podocyte damage, occurred in children with coeliac disease, CMV infection and a variant in heterozygosis for the *ACTN4* gene.

Please cite this paper as: Fortarezza F, Fiore MG, Rossini M, Piscitelli D, Gesualdo L, Resta L, et al. Steroid-resistant minimal change disease with ballooned podocytes. J Nephropathol. 2019;8(2):e19. DOI: 10.15171/jnp.2019.19.

A 3-year-old male presented with 1.7 g/d proteinuria and resolving CMV infection (negative serum DNA and ongoing IgM-IgG transition). Meanwhile, the patient presented post-prandial abdominal pain and coeliac disease was diagnosed. Laboratory data showed tissue transglutaminase IgA >200 UI, endomysial antibody IgA positive and HLA-DQ2 haplotype. A kidney biopsy was performed; the podocytes showed extensive cytoplasmic vacuolization (Figure 1A). No alteration of tubulointerstitial compartments was identified. Routine immunofluorescence and tissue PCR for CMV-DNA were negative. Electron microscopy showed the podocytes with the cytoplasm replaced by a large central vacuole that compresses the nuclei to the periphery (Figure 1B and 1C). Furthermore, a diffuse effacement of foot process was presented (Figure 1D). The diagnosis of minimal change disease was made. To rule out possible genetic causes of proteinuria, “next generation sequencing analysis” was performed for all genes known to be associated with nephrotic syndrome (60 genes), tubulopathies (47 genes) and accumulation diseases (including Fabry disease). Genetic screening was negative except for a variant in heterozygosis for the *ACTN4* gene, coding for α -actinin (R310Q). This variant was present in heterozygosis in the

patient’s father, grandmother and paternal uncles. The father had a transplant kidney at 18 years old; his nephropathy was diagnosed a year before in terminal uremic phase and renal

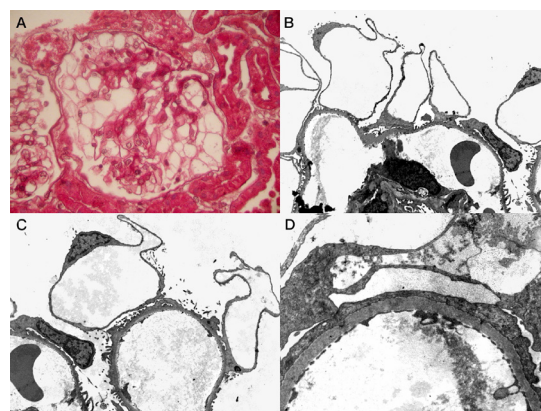


Figure 1 (A, B, C and D). The glomerulus showed extensive podocytes vacuolization with signet ring or adipocytes-like morphology (A; PAS, original magnification $\times 400$). The cytoplasm of the podocytes appears to be replaced by a single central vacuole that pushes the nucleus to the periphery (B; original magnification $\times 2800$, C; original magnification $\times 3500$). Diffuse effacement of foot process was evident, interesting more than 80% of the capillary loops. No electron-dense deposits have been identified (D; original magnification $\times 11000$).

*Corresponding author: Francesco Fortarezza, Email: francescofortarezza.md@gmail.com

biopsy revealed end-stage kidney. α -actinin 4 deficiency occurs in many glomerulopathies, including sporadic focal and segmental glomerulosclerosis, minimal change disease and IgA nephropathy. The R310Q variant do not alter actin-binding domain, but inhibit the interaction of α -actinin 4 with CLP36, with impairment of the RhoA signal transduction pathway and consequent defective traction power of the podocyte (1). The proteinuria was steroid resistant, cyclosporine and angiotensin converting enzyme (ACE) therapy led to partial remission (0.5 g/d). Six months later the gluten-free diet, the abdominal pain was resolved with the normalization of endomysial antibody IgA and tissue transglutaminase IgA but the proteinuria has remained constant. Therefore, the celiac disease does not seem to be responsible for the glomerular disease. Could the CMV infection plays a role for the unusual pattern of podocyte damage described, acting as trigger on this genetic substrate? The renal involvement in CMV infection is particularly studied in transplant pathology. Furthermore, a link with same podocytopathies is identified, as in collapsing glomerulopathy (2). The question is currently without a precise answer and the patient will be subjected to new biopsy after 24 months observation.

Authors' contribution

FF and MR prepared the manuscript and the figures; MGF,

DP and RR performed morphological evaluation; LG and LR conceived and designed the study and reviewed the manuscript. All authors gave final approval for publication.

Conflicts of interest

Authors declare no conflict of interest.

Ethical considerations

Ethical issues (including plagiarism, data fabrication, double publication) have been completely observed by the author. Consent of patient was obtained for report.

Funding/Support

None.

References

1. Liu Z, Blattner SM, Tu Y, Tisherman R, Wang JH, Rastaldi MP, et al. Alpha-actinin-4 and CLP36 protein deficiencies contribute to podocyte defects in multiple human glomerulopathies. *J Biol Chem.* 2011;286(35):30795-805. doi: 10.1074/jbc.M111.255984.
2. Barisoni L, Schnaper HW, Kopp JB. Advances in the biology and genetics of the podocytopathies: implications for diagnosis and therapy. *Arch Pathol Lab Med.* 2009;133(2):201-16.

Copyright © 2019 The Author(s); Published by Society of Diabetic Nephropathy Prevention. This is an open-access article distributed under the terms of the Creative Commons Attribution License (<http://creativecommons.org/licenses/by/4.0>), which permits unrestricted use, distribution, and reproduction in any medium, provided the original work is properly cited.