




# Journal of Nephropathology

CrossMark  
click for updates

## Renal transplantation in a patient with MYH9-related disease; a case report

Sepideh Zununi Vahed<sup>1</sup> , Bahram Niknafs<sup>1</sup> , Hamid Noshad<sup>1</sup>, Ramin Tolouian<sup>2</sup>, Mohammadali Mohajel Shoja<sup>3</sup>, Audrey Tolouian<sup>4</sup>, Mohammadreza Ardalan<sup>1\*</sup> 

<sup>1</sup>Kidney Research Center, Tabriz University of Medical Sciences, Tabriz, Iran

<sup>2</sup>Division of Nephrology, University of Arizona, Tucson, AZ, USA

<sup>3</sup>Department of Surgery, University of Texas Medical Branch, Galveston, TX, USA

<sup>4</sup>School of Nursing, University of Texas, El Paso, TX, USA

### ARTICLE INFO

*Article type:*  
Case Report

*Article history:*  
Received: 20 December 2019  
Accepted: 14 March 2020  
Published online: 7 May 2020

*Keywords:*  
MYH9-related disease, thrombocytopenia, Mutations, Gene sequencing, non-muscle myosin IIA, Renal transplant, Large platelets, End-stage renal disease

### ABSTRACT

MYH9-related diseases (MYH9-RD) are clinically represented by thrombocytopenia, large platelets, proteinuria and various degrees of renal dysfunction. We present a 25-year-old male with thrombocytopenia, large platelets, renal dysfunction and proteinuria. Gene sequencing of whole exons of *MYH9* gene confirmed the diagnosis of MYH9-related disorder and revealed single nucleotide polymorphisms (SNPs) in the introns 13 (rs3752462) and 14 (rs2413396) and a mutation in exon 26 of *MYH9* gene. Our result supported the possibility of non-coding SNPs involvement in the pathogenicity of the MYH9-RD disease and successful renal transplant in this patient.

### *Implication for health policy/practice/research/medical education:*

It is important to consider the possibility of macro-platelet-thrombocytopenia (MTCP) in patients with thrombocytopenia and renal involvement, otherwise unnecessary therapeutic plasma exchange and immunosuppressive therapy may create deleterious side effects without bringing any benefit.

*Please cite this paper as:* Zununi Vahed S, Niknafs B, Noshad H, Tolouian R, Mohajel Shoja M, Tolouian A, et al. Renal transplantation in a patient with MYH9-related disease; a case report. J Nephropathol. 2021;10(x):exx. DOI: 10.34172/jnp.2021.xx.

### Introduction

The combination of thrombocytopenia with renal disease happens in various clinical scenarios including thrombotic thrombocytopenia purpura, hemolytic-uremic syndrome, drug-induced and cancer-related thrombotic microangiopathy, systemic lupus erythematosus, antiphospholipid syndrome and advanced liver disease (1). Yet, macro-platelet-thrombocytopenia (MTCP) with glomerular involvement is a rare combination that needs clinical vigilance for its proper diagnosis and appropriate management.

Historically, a combination of deafness, nephritis and MTCP was first reported by Epstein et al in 1972, as an autosomal dominant disorder. Subsequently,

leukocyte inclusions and cataract were added to Epstein's description by Fechner, resulting in a new syndrome in his name (2,3). However, hematologists were aware of two other autosomal dominant MTCP syndromes named; Sebastian and May-Hegglin anomaly syndromes. In the first, leukocytes inclusion bodies were prominent, but in both syndromes, the renal involvement and deafness were absent. Later, these two distinct descriptions and nominations were unified under the mutated *MYH9* gene at chromosome 22q 11-13 loci. This gene encodes a cytoskeletal contractile protein as the non-muscle myosin heavy chain IIA (NMMHC-IIA). It resides at the end of myosin molecule and interacts with actin fibrils in podocytes, auditory Corti organ, leukocytes and platelets.

\*Corresponding author: Prof. Mohammadreza Ardalan,  
Email: ardalan34@yahoo.com, ardalanm@tbzmed.ac.ir

MYH9-related disease (MYH9-RD) is a conclusive and umbrella terminology for all those aforementioned syndromes.

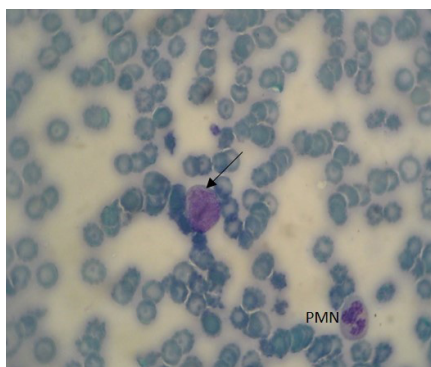
### Case Presentation

Patient was a 25-year-old man who was consulted for evaluation of nephrotic range proteinuria and hypertension. He was diagnosed with idiopathic thrombocytopenic purpura about nine years prior this admission. He had received multiple courses of corticosteroid and intravenous immuno-globulin therapy without any meaningful success over those years. He underwent splenectomy at the age of 21 due to refractory thrombocytopenia. He was a farmer, single and denied using tobacco, alcohol or exposure to hazardous materials. Two of his second cousins had similar histories of proteinuria and bleeding diathesis due to refractory thrombocytopenia. Both had been on chronic hemodialysis but had passed away years ago.

Laboratory examination revealed anemia [hemoglobin 10 g/dL], leukocytosis [WBC's 17000/ $\mu$ L] and thrombocytopenia [PLT 31000/ $\mu$ L]. The coagulation, liver profiles and LDH were within normal range. Serum creatinine was 4 mg/dL. Urine analysis showed protein 4+ and RBC 9-10/high power field (hpf). 24-hour urine protein was 3100 mg/day. Serologic markers including, antinuclear antibody, anti-neutrophilic cytoplasmic antibody, anti-dsDNA, anti-glomerular basement membrane antibody, anti-cardiolipin Ab, HBsAg and anti-HCV Ab, all were normal. Complement activating factors of C3, C4 and CH50 and inhibitory factors of H (CFH) and I (CFI) were in normal range. The activity of ADAMTS 13 was 110 % (normal; 40-130). Peripheral blood smear was remarkable for thrombocytopenia with giant platelet with no schistocytes.

Abdominal ultrasound showed normal sized kidneys with no hydronephrosis, liver was normal, splenectomy, no ascites or para-aortic lymphadenopathy (Figure 1).

Bone marrow study was unremarkable. Ultrasound



**Figure 1.** Peripheral blood smear Giemsa staining ( $\times 40$ ). Large platelet (arrow) that are larger than polymorphonuclears (PMN) in the fields.

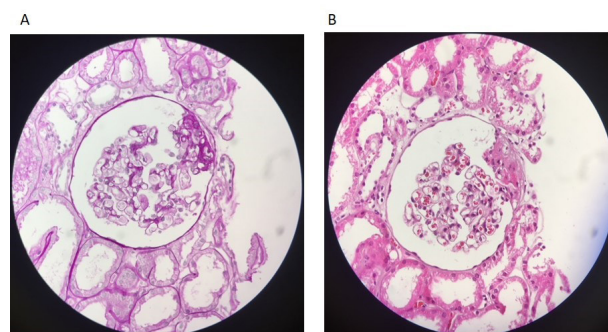
guided renal biopsy was performed with great caution. The light microscopic was consistent with focal segmental glomerulosclerosis (FSGS) (Figure 2) since immunofluorescence study was negative. He was taking angiotensin receptor blocker (losartan 25 mg twice daily) and glucocorticoid (prednisolone 10 mg/d). During his hospitalization, the glucocorticoid was stopped and he continued with losartan, for proteinuria.

Gene sequencing of whole exons of *MYH9* gene was performed to confirm the diagnosis of MYH9-related disorder. The DNA sample was negative for causative point mutation, small deletion or duplication in the coding and splice regions of *MYH9* gene in high-throughput sequencing. However, A c.1554+7A>G mutation in intron 13 (SNP rs3752462), a c.1728+10G>A mutation in intron 14 (SNP rs2413396) and a c.3429T>G mutation in exon 26 were observed.

Then, the patient's renal function gradually deteriorated and hemodialysis was initiated. Soon after, the patient received a living, unrelated-renal transplantation. Post-operative clinical course was complicated with bleeding and large perinephric hematoma formation. Patient was treated with platelet transfusion and drainage of periallograft blood collection. The patient was discharged with normal renal allograft function. Three years after transplantation, mild thrombocytopenia (PLT ~ 70 000) without any bleeding episodes and stable renal allograft function (serum creatinine; 1.2 mg/dL) were noted.

### Discussion

In the present study, despite classic phenotypic presentations of macro-platelet thrombocytopenia syndrome, none of the previously reported genetic mutations in whole exons of *MYH9* gene were found. However, three SNPs were observed in introns 13 (rs3752462), 14 (rs2413396) and exon 26 (rs710181). Our finding was in concordance with the study by Nelson et al, who found a strong association between kidney disease and SNPs in introns 13 to 15



**Figure 2.** Glomerular staining ( $\times 40$ ). (A) PAS and (B) H&E staining. Mild peri-hilar sclerosis (FSGS) with open vascular spaces, without intracapillary or extracapillary proliferation. FSGS (focal segmental glomerulosclerosis).

of *MYH9* gene (4). SNP rs2413396 in exon 14 is a risk variant and has the strongest recessive association with FSGS development, as it modifies splice-determining motifs of the NMMHCIIA protein; therefore, affects its normal splicing and expression (4). Our results support the possibility of non-coding SNPs involvement in the pathogenicity of the MYH9-RD.

NMMHCIIA protein, coded by *MYH9*, is expressed highly in mesangial cells and podocytes and has a key role in the actin myosin contractile machine to preserve the structure of the podocyte foot process. Disruption of NMMHCIIA protein leads to podocyte collapse, damage in glomerular filtration barrier and consequently, proteinuria and glomerular sclerosis (5). A variety of mutations comprising of 44 different changes is reported in the *MYH9* gene, mostly amino acids substitutions (6). Missense mutations in MYH9-R influence the head or tail domain of the NMHC IIA in most cases, while nonsense or frameshift modifications lead to the deletion in a C-terminal fragment of the protein (7, 8). It is suggested that several *MYH9* gene SNPs can predict kidney disease (9,10). In 2008, *MYH9* gene was considered as a risk factor for non-diabetic end-stage renal disease and FSGS in African (11,12). However, the idea soon shifted toward the neighboring region on chromosome 22q12.3 and apolipoprotein L1 (*APO1*) risk variants (11-13).

Renal biopsy is a risky procedure in patients with MTCP. The expected renal involvement in this condition is FSGS and ours was the same. We do not recommend conducting a renal biopsy due to risk of bleeding in MTCP. Renal transplant is a valuable option in this scenario. Although, there was a risk of bleeding, in our case it was easy to manage. FSGS in this disease is caused by podocytes MYH9-related structural damage and not due to a circulating factor. Therefore, we did not expect for proteinuria recurrence after renal transplant. Three years post-renal transplant follow up patient did not show any recurrence of proteinuria in our case. There are not several reports of renal transplant in MYH9-related disease. We speculate that patient survival should be shorter in this population due to underlying disease. Since, the renal allograft has normal podocyte structure; therefore, we are assuming that 5-year or even 10-year renal/graft survival should be equal or even better than its control.

### Conclusion

MYH9-related diseases are rare clinical syndromes. It is a structural abnormality of non-muscle myosin IIA heavy chain. Its clinical presentations are complex and ranging from podocytopathy to platelet structural impairment. Lack of knowledge about this abnormality may lead to misdiagnosis and mismanagement of the disease. This is a rare case report of a successful renal transplantation in a

MYH9-RD patient.

### Authors' contribution

MRA selected the case and designed the study. BN, HN and RT performed the interpretation of the data. SZV, AT, RT prepared and edited the draft. All authors read and signed the final paper.

### Conflicts of interests

The authors declared no potential conflicts of interest with respect to the authorship, research and/or publication of this article.

### Ethical considerations

This study was approved by the committee of clinical research ethics of Tabriz university of medical sciences (Ethical code: IR.TBZMED.REC.1396.977). Written informed consent was obtained from the patient after enough explanation of the study. Additionally, ethical issues including data fabrication, plagiarism and double publication have been completely observed by the authors.

### Funding/Support

This work was financially supported by the Kidney Research Center at Tabriz University of Medical Sciences, Tabriz, Iran.

### References

1. Barbour T, Johnson S, Cohny S, Hughes P. Thrombotic microangiopathy and associated renal disorders. *Nephrol Dial Transplant*. 2012;27:2673-85. doi: 10.1093/ndt/gfs279.
2. Kelley MJ, Jawien W, Ortel TL, Korczak JF. Mutation of MYH9, encoding non-muscle myosin heavy chain A, in May-Hegglin anomaly. *Nat Genet*. 2000;26:106-8. doi: 10.1038/79069.
3. Knebelmann B, Fakhouri F, and Grunfeld JP. Hereditary nephritis with macrothrombocytopenia: no longer an Alport syndrome variant. *Nephrol Dial Transplant*. 2001;16:1101-3. doi: 10.1093/ndt/16.6.1101.
4. Nelson GW, Freedman BI, Bowden DW, Langefeld CD, An P, Hicks PJ, et al. Dense mapping of MYH9 localizes the strongest kidney disease associations to the region of introns 13 to 15. *Hum Mol Genet*. 2010;19:1805-15. doi: 10.1093/hmg/ddq039.
5. Ghiggeri GM, Caridi G, Magrini U, Sessa A, Savoia A, Seri M, et al. Genetics, clinical and pathological features of glomerulonephritis associated with mutations of nonmuscle myosin IIA (Fechtner syndrome). *Am J Kidney Dis*. 2003;41:95-104. doi: 10.1053/ajkd.2003.50028
6. Balduini CL, Pecci A, and Savoia A. Recent advances in the understanding and management of MYH9-related inherited thrombocytopenias. *Br J Haematol*. 2011;154(2):161-74. doi: 10.1111/j.1365-2141.2011.08716.x.
7. Pecci A, Klersy C, Gresele P, Lee KJ, De Rocco D, Bozzi V, et al. MYH9-related disease: a novel prognostic model to predict the clinical evolution of the disease based on genotype-

- phenotype correlations. *Hum Mutat.* 2014;35:236-47. doi: 10.1002/humu.22476.
8. Saposnik B, Binard S, Fenneteau O, Nurden A, Nurden P, Hurtaud-Roux MF, et al. Mutation spectrum and genotype-phenotype correlations in a large French cohort of MYH9-Related Disorders. *Mol Genet Genomic Med.* 2014;2:297-312. doi: 10.1002/mgg3.68.
  9. Freedman BI, Hicks PJ, Bostrom MA, Cunningham ME, Liu Y, Divers J, et al. Polymorphisms in the non-muscle myosin heavy chain 9 gene (MYH9) are strongly associated with end-stage renal disease historically attributed to hypertension in African Americans. *Kidney Int.* 2009;75:736-45. doi: 10.1038/ki.2008.701.
  10. Behar DM, Rosset S, Tzur S, Selig S, Yudkovsky G, Bercovici S, et al. African ancestry allelic variation at the MYH9 gene contributes to increased susceptibility to non-diabetic end-stage kidney disease in Hispanic Americans. *Hum Mol Genet.* 2010;19(9):1816-27. doi: 10.1093/hmg/ddq040.
  11. Kopp JB, Smith MW, Nelson GW, Johnson RC, Freedman BI, Bowden DW, et al. MYH9 is a major-effect risk gene for focal segmental glomerulosclerosis. *Nat Genet.* 2008;40:1175-84. doi: 10.1038/ng.226.
  12. Kao WH, Klag MJ, Meoni LA, Reich D, Berthier-Schaad Y, Li M, et al. MYH9 is associated with nondiabetic end-stage renal disease in African Americans. *Nat Genet.* 2008;40:1185-92. doi: 10.1038/ng.232.
  13. Genovese G, Friedman DJ, Ross MD, Lecordier L, Uzureau P, Freedman BI, et al. Association of trypanolytic ApoL1 variants with kidney disease in African Americans. *Science.* 2010;329:841-5. doi: 10.1126/science.1193032.

**Copyright** © 2020 The Author(s); Published by Society of Diabetic Nephropathy Prevention. This is an open-access article distributed under the terms of the Creative Commons Attribution License (<http://creativecommons.org/licenses/by/4.0>), which permits unrestricted use, distribution, and reproduction in any medium, provided the original work is properly cited.