

# Journal of Nephropathology



## Crescentic membranoproliferative glomerulonephritis in HIV infection; a mini-review with case study

Priti Meena<sup>1\*</sup>, Vinant Bhargava<sup>1</sup>, Devinder Singh Rana<sup>1</sup>, Anil Kumar Bhalla<sup>1</sup>, Ashwani Gupta<sup>1</sup>, Manish Malik<sup>1</sup>, Pallav Gupta<sup>2</sup>

<sup>1</sup>Institute of Renal Science, Sir Gangaram Hospital, New Delhi, India

<sup>2</sup>Department of Renal Pathology, Sir Gangaram Hospital, New Delhi, India

### ARTICLE INFO

*Article type:*  
Review

*Article history:*  
Received: 20 November 2020  
Accepted: 14 January 2021  
Published online: 26 January 2021

*Keywords:*  
Crescentic glomerulonephritis, HIV,  
Urinary abnormalities, HIV-associated  
nephropathy

### ABSTRACT

HIV-related renal diseases have become more evident and easier to treat due to the prolonged survival of patients with HIV infection on antiretroviral therapy (ART). There are multiple factors involved in the pathogenesis of this entity. However, very little has been described regarding secondary membranoproliferative glomerulonephritis and especially a crescentic disease in these patients. Herein, we describe a patient who was incidentally detected to have HIV infection while evaluating for a rapidly progressive renal failure and was detected to have crescentic glomerulonephritis. We have reviewed the literature pertinent to the case in the present report.

### *Implication for health policy/practice/research/medical education:*

This unique presentation of HIV infection manifesting as a crescentic presentation in the kidney is difficult to treat and lacks literature guided treatment options. It presents with challenges regarding diagnosis, management and use of immunosuppressive protocols, plasmapheresis and highly active ART.

*Please cite this paper as:* Priti M, Bhargava V, Singh Rana D, Kumar Bhalla A, Gupta A, Malik M, Gupta P. Crescentic membranoproliferative glomerulonephritis in HIV infection; a mini-review with case study. J Nephropathol. 2021;10(x):exx. DOI: 10.34172/jnp.2021.xx.

### Introduction

The initial 25 years of the human immunodeficiency virus (HIV) epidemic, saw HIV-associated nephropathy (HIVAN) surpassing other causes of kidney diseases leading to end-stage renal diseases (ESRD) (1). The understanding of pathogenetic mechanisms of HIVAN has undergone a paradigm evolution over the past 15 years. It has been proven that there is an unambiguous association of HIV-1 infection with the renal lesions, while the identification of a genetic susceptibility locus (MYH9/APOL1) for the development of HIVAN in African-Americans (2-5) has made it more exciting. A decline in the incidence of ESRD due to HIVAN after the introduction of highly active antiretroviral therapy (ART) suggests a beneficial role for ART in preventing the development of HIVAN associated ESRD. Classical HIV related renal disease was previously recognized as a rapidly progressing renal failure with heavy proteinuria in a black race patient. It

was a classical collapsing FSGS presentation. However, over the years, a wide spectrum of histopathological findings including membranous glomerulopathy, thrombotic microangiopathy membranoproliferative glomerulonephritis, IgA nephropathy, diffuse proliferative glomerulonephritis, and crescentic glomerulonephritis have also been recognized. In the highly active antiretroviral therapy (HAART) era, medication side effects such as nephrolithiasis, acute kidney injury, and proximal tubular toxicity have become more common. The presence of other comorbidities such as old age, smoking, hypertension, dyslipidemia, and dysregulated glucose homeostasis have contributed to a further increase in the incidence of chronic kidney disease in these patients. In our patient, we describe a rare presentation of membranoproliferative glomerulonephritis (MPGN) with the development of a crescentic histomorphological pattern secondary to HIV infection.

\*Corresponding author: Meena Priti,  
Email: pritimn@gmail.com, gangaram@sgrh.com

### Case Presentation

A 46-year-old Indian male presented with a history of easy fatigability, unintentional weight loss, and reduced appetite of 1-month duration. He noticed a reduction in the urine output for three days duration but denied any history of anasarca, hematuria, pyuria, abdominal pain, or breathlessness. There was no history of cough, fever with chills, night sweats, and chronic diarrhea. He was not suffering from any prior co-morbidities such as hypertension, hypothyroidism, diabetes mellitus, or prior renal dysfunction. He was a non-smoker, non-consumer of alcohol, and had never taken or injected recreational drugs. He confirmed exposure to commercial sex workers two years prior to presentation. There was no family history of kidney disease. On physical examination, he was afebrile, normotensive, mildly edematous, and had pallor. There was no oral thrush, lymphadenopathy. No abnormality was detected on the respiratory and cardiovascular examination. There was no organomegaly. Laboratory investigations showed hemoglobin 8.5 g/dL, platelet count 150 000/ $\mu$ L, total white cell count 5000 cells/ $\mu$ L. Renal profile was as follows; sodium 138 mmol/L, potassium 6.5 mmol/L, chloride 110 mmol/L, serum bicarbonate 10 mmol/L, blood urea nitrogen 160 mg/dL, serum creatinine 12.4 mg/dL, alkaline phosphatase 267 units/L. The chest X-ray was normal. Urinalysis revealed specific gravity 1.010, pH 6.0, albuminuria 2+, glucose-negative, WBC 3-4/hpf, and RBC 10-15/hpf.

Additionally, 24-hour urinary protein estimation was 3.8 grams. Fundus examination revealed no abnormality. Renal ultrasonography demonstrated normal size and contour of both the kidneys. Serology for HIV by both ELISA and western blot method was reported to be reactive. The patient underwent several sessions of uncomplicated hemodialyses via the right internal jugular dialysis catheter. He had a CD4+ T cell count of 192 cells/ $\mu$ L. His CD8+ T lymphocytes were 900 cells/ $\mu$ L. He was detected to have HIV-1 RNA level of 4200 copies/ml. He underwent an uncomplicated kidney biopsy. The light microscopy showed 20 glomeruli, out of which 17 showed crescents (8 cellular and 9 fibro-cellular). There was thickening of the glomerular capillary walls with mesangial proliferation and an increase in the mesangial matrix giving lobular accentuation to glomerular tuft. Blood vessels were unremarkable. Moderate amount of interstitial fibrosis and tubular atrophy was seen. The immunofluorescence technique revealed fluorescent deposits of IgM (3+), C3 (3+), C1q (3+) granular mesangial, and along the GBM, kappa (4+), lambda (4+). IgA and IgG were negative. He was evaluated further and detected to have raised erythrocyte sedimentation rate 80 mm/h with negative ANA (both ELISA and IIF), ANCA

(c/p; ELISA), and anti-GBM (EIA) antibodies. The serum protein electrophoresis, C3, and C4 levels were normal. HAART was initiated. He was given methylprednisolone 250 mg/d for 3 days then shifted to oral prednisone with a dose of 1 mg/kg for 2 weeks. The treatment was discontinued due to the non-recovery of signs and symptoms and subsequent development of fever. The patient is presently maintained on dialysis of a thrice-weekly regimen, and a left radio cephalic AV fistula was created. He is on regular outpatient follow up for the last three months and tolerating HAART well. His last CD4 was 1040 cells/ $\mu$ L and did not present with any infectious complications (Figures 1 and 2).

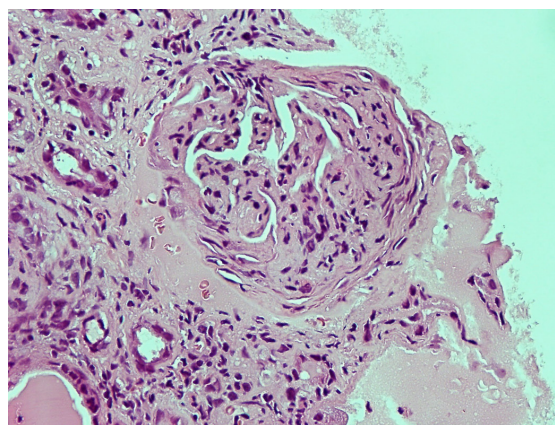
### Review of the literature

With the increasing longevity of patients with HIV infection owing to the advancement of treatment, there is a progressive change in the spectrum of kidney injury in HIV patients, and kidney disease is no more synonymous with HIVAN. In HIV-infected patients, MPGN is the most common histological pattern of immune complex-mediated glomerulonephritis (ICGN) (6).

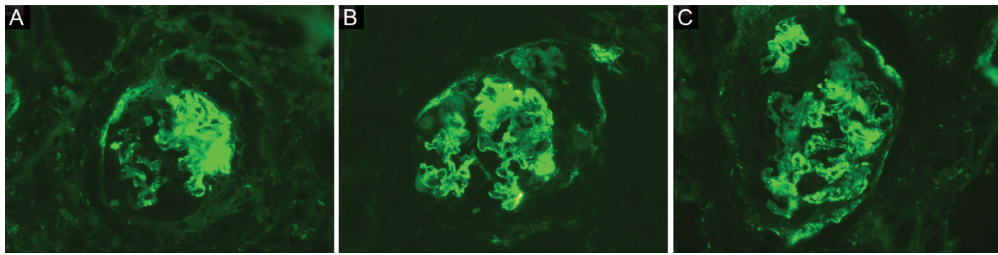
### Immune complex GN in HIV related kidney disease

The pathogenesis of ICGN in HIV-infected patients is yet to be elucidated. Literature provides a direct causal relationship between HIV and glomerular lesions. In HIV, polyclonal B-cell activation with hypergammaglobulinemia is commonly seen. In immune complexes from the circulation, HIV antigen has been detected. It has also been isolated from kidney biopsy of HIV-infected patients (7), supporting direct causal pathogenic involvement of HIV in the development of ICGN.

The other possibilities may be a secondary or an unusual response to coexistent intercurrent infections, or probably



**Figure 1.** Photomicrograph showing fibrocellular crescent (H&E  $\times$ 40).



**Figure 2.** Immunofluorescence demonstration of positive staining for immune reactants C1q, C3, IgM (A, B, C, respectively) in the glomeruli.

a coincidental finding. There is possibly a role of host genetic factors in modulating the phenotypic expression of renal disease, as suggested by the different racial proclivity for kidney injury (8-10). There have been reports of clustering of kidney disease in families of patients with HIV and ESRD (11). The pathologic classification of various patterns of HIV-related kidney diseases is shown in Figure 3 (12).

#### Pathogenesis of HIV related kidney diseases

The development of kidney injury in an HIV-infected patient requires co-existence of various factors mediated by the host, i.e., genetic susceptibility, host immune response leading to microenvironment for immune activation critical for renal damage mediated by cytokines, growth factor, and chemokine and their responses. Bruggeman et al (13) showed that peculiar histological and functional changes were induced by a particular viral regulatory or accessory proteins. These proteins have intricate effects on host cell involving CD4 expression, apoptosis regulation, cytokines production, and response. For example, focal glomerulosclerosis may be induced by *Tat* and *Vpr* gene, and *Nef* may contribute to interstitial nephritis (14).

Selective podocyte injury is also found in HIV. There is a phenotypical alteration in podocytes caused by dedifferentiation and dysregulation, as reflected by loss of podocyte markers like synaptopodin and Wilms' tumor protein (15). The peculiar loss of podocalyxin favors the postulation of selective podocyte injury in HIV. The collagen synthesis shifts from collagen 3, 4, chain to collagen 1 and 2 chain (fetal composition) in dedifferentiated podocyte and collapsed glomeruli (16).

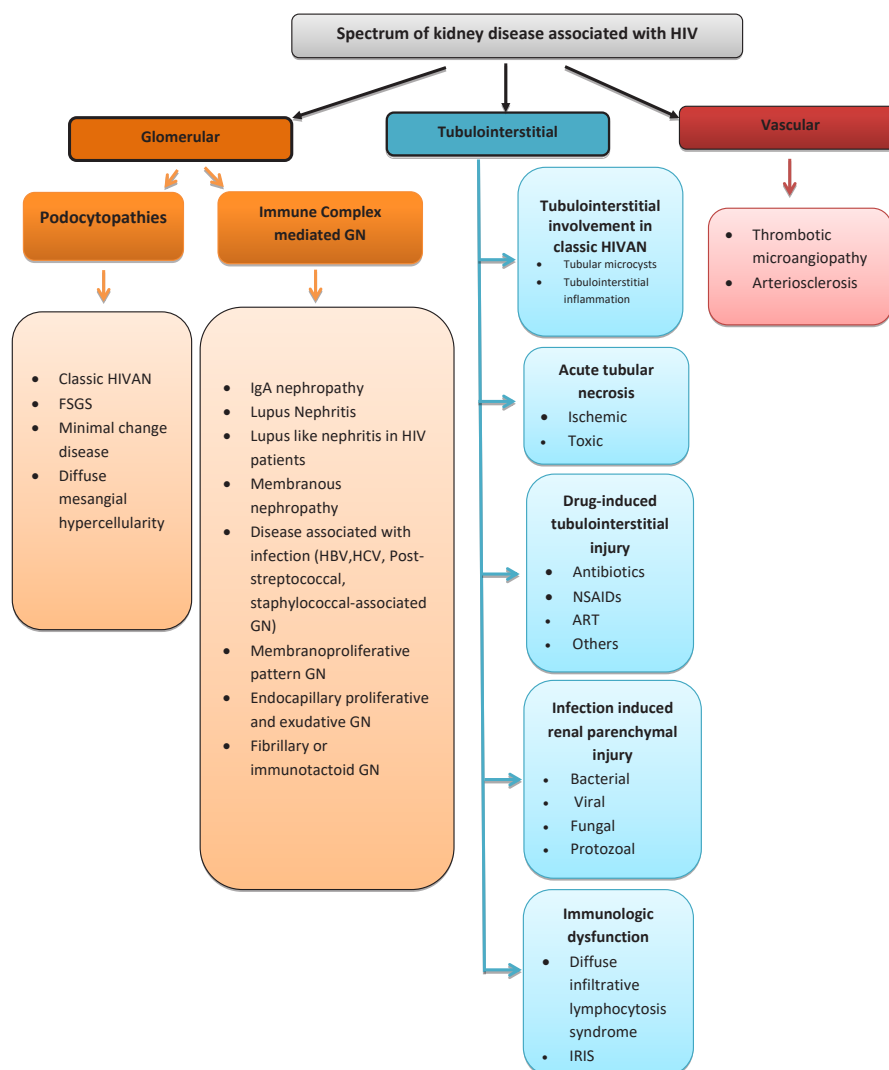
#### HIV-associated nephropathy

HIVAN typically presents with nephrotic range proteinuria, and ultrasound shows large echogenic kidneys. It leads to rapid progression to ESRD, especially in the African-American population (17). Sometimes HIVAN is the earliest manifestation in HIV patients even when the patient is asymptomatic. Light microscopy in HIVAN shows collapsing glomerulopathy with concomitant

changes in tubulointerstitium comprising tubular microcyst formation, tubular injury, and interstitial inflammation. Glomerular "collapse" is defined when at least one glomerulus shows the collapse of glomerular basement membrane in addition to hyperplasia and/or hypertrophy of the glomerular epithelial cells (18). Pseudo-crescents may be present in Bowman's space formed by hyperplastic cells. In immunofluorescence findings, IgM, C3, and C1q staining may be present in mesangial areas along with collapse segments and diffuse effacement of podocyte foot process and tubuloreticular inclusions in endothelial cells are the characteristic of electron microscopy. The presence of tubuloreticular inclusions envision the aggressive clinical course of the disease and distinguish it from other forms of renal injury like idiopathic FSGS (19).

#### HIV-associated immune complex kidney disease and other glomerular dominant diseases

The reported incidence of HIV-associated immune complex kidney disease (HIVICK) is 37%–76% in kidney biopsy specimens (7). Numerous histological patterns of immune complex-mediated glomerular disease are reported in HIV patients. Foy et al in his survey of renal biopsies of HIVICK in Johns Hopkins HIV clinical cohorts reported various patterns such as postinfectious GN (41%), IgA nephropathy (8%), membranoproliferative GN (7%), membranous nephropathy (5%), lupus-like GN (11%), immune complex GN not otherwise specified (11%) (20). Several other series have shown that 18%–45% of HIVICK are contributed by lupus-like nephritis. In this entity, histologic features are indistinguishable from lupus nephritis, but clinical or serologic markers of systemic lupus are absent (21). It is also a well-recognized cause of ESRD in HIV patients. The pathogenesis of HIVICK is not well described because of its heterogeneous spectrum and the lack of evidence to prove its causality from HIV. Other than activation of polyclonal B-cell with hypergammaglobulinemia, the detection of IgA or IgG-HIV immune complexes in biopsy specimens in some of the studies suggests the role of HIV-binding antibodies



**Figure 3.** HIV-related kidney diseases. HIVAN, HIV-associated nephropathy; FSGS, focal segmental glomerulosclerosis; GN, glomerulonephritis; ICGN- immune complex mediated glomerulonephritis; IRIS, Immune reconstitution inflammatory syndrome; ART, antiretroviral therapy; NSAIDs, non-steroidal anti-inflammatory drugs.

in immune complex formation. These patients present with hypertension, reduction in eGFR, subnephrotic proteinuria, and haematuria. The mechanism of other glomerular patterns is less known, and it is yet to be proven whether the pathogenesis of IgA nephropathy in HIV is related to undergalactosylated IgA1 or IgA deposition against the viral antigen. One should also rule out co-infection with hepatitis B and hepatitis C virus, syphilis, presence of anti-PLA2R autoantibodies (as in membranous nephropathy). There are only a few studies available for the treatment in patients with HIVICK. In a US multicenter cohort, HAART does not affect the progression of non-HIVAN kidney disease (18), although some other studies have suggested some beneficial role of HAART (19). The management has principally concentrated on abating the production of immune complexes by suppressing viral

replication. However, this may not be ample to mitigate disease progression. Reducing the inflammatory response may be additionally required. Although the long-term consequences of HIV-associated lupus-like nephritis are less studied, poor renal survival has been reported in some series (12), with the development of ESRD in up to 71% within a year of detection, and no apparent benefit from HAART or immunosuppression (22).

### Crescentic glomerulonephritis in HIV related renal disease

MPGN pattern is associated with immune complex deposition. Crescentic proliferation with no immune deposition is an unusual and atypical presentation in HIV. In HIV associated MPGN, a crescentic transformation has been very rarely reported. Some of the important

**Table 1.** Renal histology in HIV-review of literature

Study	No of patients (n)	Crescentic glomerulonephritis (%)	HIVAN (%)	Immune complex disease (%)
Lescure et al (26)	88	1.1	26	20
Berliner et al (23)	152	0.7	34.9	25
Vali et al(27)	27	1.5	22.5	24
Columbia-Presbyterian Medical Center (28)	112	Not specified	73	17
D'Agati et al (29)	136	Not specified	64.5	26
Varma et al (30)	25	1	33.3	2

studies are shown in Table 1, authenticating the rarity of the disease. The index patient reported here did not have any serological markers of vasculitis, which is a common cause for crescentic GN. Various other etiologies for crescentic glomerulonephritis were ruled out, since this disease was presumed to be due to direct infection with HIV-1. Unfortunately, their causal relationship could not be confirmed. Literature for non-immune mediated crescentic glomerulonephritis is very scarce. Trolliet et al reported a case of crescentic proliferation secondary to crystal deposition in glomerular capillaries in a patient with HIV on foscarnet therapy (24). Monteiro et al also reported a case of diffuse proliferative crescentic glomerulonephritis in an HIV patient who presented as rapidly progressive glomerulonephritis mediated by anti- GBM antibodies (25). Pathogenetic mechanisms to improve the association between immune dysregulation, or direct involvement of HIV in crescent formation is still unclear. The outcome of this entity appears to be dismal, and a judicial decision between the use of immunosuppression and HAART is warranted.

### Conclusion

This rare presentation of HIV-1 infection, causing a membranoproliferative histopathological pattern with a crescentic transformation, is difficult to treat and lacks literature guided treatment options. It is suggested that we should look out for this entity and be very careful regarding diagnosis, management. The use of immunosuppressive protocols, plasmapheresis, and HAART needs careful consideration. The therapy should be guided by individual experience(s) until there is adequate literature in this field.

### Authors' contribution

PM and VB were the principal investigators of the study. PG, DSR and AKB participated in preparing the concept and design. MM and AG revisited the manuscript and critically evaluated the intellectual contents. All authors participated in preparing the final draft of the manuscript, revised the manuscript and critically evaluated the intellectual contents. All authors have read and approved

the content of the manuscript and confirmed the accuracy or integrity of any part of the work.

### Conflicts of interest

The authors declare that they have no competing interests.

### Ethical considerations

Ethical issues including plagiarism, double publication, and redundancy, have been completely observed by the author. Written informed consent was obtained from the patient.

### Funding/Support

None.

### References

- Vigneau C, Guiard-Schmid JB, Tourret J, Flahault A, Rozenbaum W, Pialoux G, et al. The clinical characteristics of HIV-infected patients receiving dialysis in France between 1997 and 2002. *Kidney Int.* 2005;67(4):1509-14. doi: 10.1111/j.1523-1755.2005.00229.
- Snyder A, Alsauskas ZC, Leventhal JS, Rosenstiel PE, Gong P, Chan JJ, et al. HIV-1 viral protein r induces ERK and caspase-8-dependent apoptosis in renal tubular epithelial cells. *AIDS.* 2010;24(8):1107-19. doi: 10.1097/QAD.0b013e328337b0ab
- Kasembeli AN, Duarte R, Ramsay M, Mosiane P, Dickens C, Dix-Peek T, et al. APOL1 Risk Variants Are Strongly Associated with HIV-Associated Nephropathy in Black South Africans. *J Am Soc Nephrol.* 2015;26(11):2882-90. doi: 10.1681/ASN.2014050469.
- Kopp JB, Nelson GW, Sampath K, Johnson RC, Genovese G, An P, et al. APOL1 genetic variants in focal segmental glomerulosclerosis and HIV-associated nephropathy. *J Am Soc Nephrol.* 2011;22(11):2129-37. doi: 10.1681/ASN.2011040388.
- Szczech LA, Gupta SK, Habash R, Guasch A, Kalayjian R, Appel R, et al. The clinical epidemiology and course of the spectrum of renal diseases associated with HIV infection. *Kidney Int.* 2004;66(3):1145-52. doi: 10.1111/j.1523-1755.2004.00865.
- Casanova S, Mazzucco G, Barbiano di Belgiojoso G, Motta M, Boldorini R, et al. Pattern of glomerular involvement

- in human immunodeficiency virus-infected patients: an Italian study. *Am J Kidney Dis.* 1995;26(3):446-53. doi: 10.1016/0272-6386(95)90490-5.
7. Kimmel PL. HIV-associated nephropathy: virologic issues related to renal sclerosis. *Nephrol Dial Transplant* 2003;18 Suppl 6:vi59-63. doi: 10.1093/ndt/gfg1062.
  8. Kofman T, Narjoz C, Raimbourg Q, Lorient MA, Karras A, Roland M, et al. Collapsing glomerulopathy associated lupus in a black female with homozygous APOL1 mutation. *Lupus.* 2012;21(13):1459-62. doi: 10.1177/0961203312460114.
  9. Praditpornsilpa K, Napathorn S, Yenrudi S, Wankrairo P, Tungasaga K, Sitprija V. Renal pathology and HIV infection in Thailand. *Am J Kidney Dis.* 1999;33(2):282-6. doi: 10.1016/s0272-6386(99)70301-x
  10. Szczech LA. Renal diseases associated with human immunodeficiency virus infection: epidemiology, clinical course, and management. *Clin Infect Dis.* 2001;33(1):115-9. doi: 10.1086/320893.
  11. Wearne N, Okpechi IG. HIV-associated renal disease - an overview. *Clin Nephrol.* 2016;86(13):41-7. doi: 10.5414/CNP86S117.
  12. Swanepoel CR, Atta MG, D'Agati VD, Estrella MM, Fogo AB, Naicker S, et al. Kidney disease in the setting of HIV infection: conclusions from a Kidney Disease: Improving Global Outcomes (KDIGO) Controversies Conference. *Kidney Int.* 2018;93(3):545-59. doi: 10.1016/j.kint.2017.11.007.
  13. Bruggeman LA. HIV-1 Infection of Renal Cells in HIV-Associated Nephropathy. *J Am Soc Nephrol.* 2017;28(3):719-21. doi: 10.1681/ASN.2016111171.
  14. Nelson PJ, Sunamoto M, Husain M, Gelman IH. HIV-1 expression induces cyclin D1 expression and pRb phosphorylation in infected podocytes: cell-cycle mechanisms contributing to the proliferative phenotype in HIV-associated nephropathy. *BMC Microbiol.* 2002;2:26. doi: 10.1186/1471-2180-2-26.
  15. Tandon R, Levental I, Huang C, Byfield FJ, Ziemicki J, Schelling JR, et al. HIV infection changes glomerular podocyte cytoskeletal composition and results in distinct cellular mechanical properties. *Am J Physiol Renal Physiol.* 2007;292(2):F701-10. doi: 10.1152/ajprenal.00246.2006.
  16. Wyss HM, Henderson JM, Byfield FJ, Bruggeman LA, Ding Y, Huang C, et al. Biophysical properties of normal and diseased renal glomeruli. *Am J Physiol Cell Physiol.* 2011;300(3):C397-405. doi: 10.1152/ajpcell.00438.2010.
  17. Husain NE, Ahmed MH, Almobarak AO, Noor SK, Elmadhoun WM, Awadalla H, et al. HIV-associated nephropathy in africa: pathology, clinical presentation and strategy for prevention. *J Clin Med Res.* 2018;10(1):1-8. doi: 10.14740/jocmr3235w
  18. Rosenberg AZ, Naicker S, Winkler CA, Kopp JB. HIV-associated nephropathies: epidemiology, pathology, mechanisms and treatment. *Nat Rev Nephrol.* 2015;11(3):150-60. doi: 10.1038/nrneph.2015.9.
  19. Phair J, Palella F. Renal disease in HIV-infected individuals. Current opinion in HIV and AIDS. 2011;6(4):285-9. doi: 10.1097/COH.0b013e3283476bc3.
  20. Foy MC, Estrella MM, Lucas GM, Tahir F, Fine DM, Moore RD, et al. Comparison of risk factors and outcomes in HIV immune complex kidney disease and HIV-associated nephropathy. *Clin J Am Soc Nephrol.* 2013;8(9):1524-32. doi: 10.2215/CJN.10991012.
  21. Tabechian D, Pattanaik D, Suresh U, Cohn SE, Nadasdy T. Lupus-like nephritis in an HIV-positive patient: report of a case and review of the literature. *Clin Nephrol.* 2003;60(3):187-94. doi: 10.5414/cnp60187
  22. Hamid CK, Hameed RA, Khaliq BI, Manzoor R, Hamid CQ. HIV associated lupus like nephropathy. *Ethiopian J Health Sci.* 2014;24(3):277-283. doi: 10.4314/ejhs.v24i3.13.
  23. Berliner AR, Fine DM, Lucas GM, Rahman MH, Racusen LC, Scheel PJ, et al. Observations on a cohort of HIV-infected patients undergoing native renal biopsy. *Am J Nephrol.* 2008;28(3):478-86. doi: 10.1159/000112851
  24. Trolliet P, Dijoud F, Cotte L, Cahen R, François B, Trepoc C, et al. Crescentic glomerulonephritis and crystals within glomerular capillaries in an AIDS patient treated with foscarnet. *Am J Nephrol* 1995;15:256-9. doi: 10.1159/000168842.
  25. Monteiro EJ, Caron D, Balda CA, Franco M, Pereira AB, Kirsztajn GM, et al. Anti-glomerular basement membrane glomerulonephritis in an HIV positive patient: case report. *Braz J Infect Dis.* 2006;10(1):55-58. doi: 10.1590/S1413-86702006000100011
  26. Lescure FX, Flateau C, Pacanowski J, Brocheriou I, Rondeau E, Girard PM, et al. HIV-associated kidney glomerular diseases: changes with time and HAART. *Nephrol Dial Transplant.* 2012;27(6):2349-55. doi: 10.1093/ndt/gfr676.
  27. Vali PS, Ismal K, Gowrishankar S, Sahay M. Renal disease in human immunodeficiency virus - Not just HIV-associated nephropathy. *Indian J Nephrol.* 2012;22(2):98-102. doi: 10.4103/0971-4065.97117.
  28. Appel GB, Nicolaidis MN. Human immunodeficiency virus/acquired immunodeficiency syndrome nephropathy in the inner city. *N Y State J Med.* 1991;91(5):207-10.
  29. D'Agati V, Appel GB. Renal pathology of human immunodeficiency virus infection. *Semin Nephrol.* 1998;18(4):406-21.
  30. Varma PP, Prasher PK, Deshpande GU, Mani NS, Nema SK, Sayal SK. Spectrum of renal lesions in HIV patients. *J Assoc Physicians India.* 2000;48:1151-4.