



Late onset primary hyperoxaluria after kidney transplantation in a 36-year-old woman

Amirhesam Alirezaei¹, Hamed Ebrahimibagha², Mahmoud Parvin³, Majid Ali Asgari⁴, Leyla Bagheri⁵

¹Department of Nephrology, Shahid Modarres Hospital, Shahid Beheshti University of Medical Sciences, Tehran, Iran

²Medical Student Research Committee, School of Medicine, Shahid Beheshti University of Medical Sciences, Tehran, Iran

³Department of pathology, Labbafinejad Medical Center, Shahid Beheshti University of Medical Sciences, Tehran, Iran

⁴Urology and Nephrology Research Center, Shahid Modarres Hospital, Shahid Beheshti University of Medical Sciences, Tehran, Iran

⁵Department of Internal Medicine, Shahid Modarres Hospital, Shahid Beheshti University of Medical Sciences, Tehran, Iran

ARTICLE INFO

Article type:
Case Report

Article history:
Received: 15 March 2020
Accepted: 20 June 2020
Published online: 22 July 2020

Keywords:
Hyperoxaluria, Nephrolithiasis, Nephrocalcinosis, End-stage renal disease, Kidney transplantation, Primary hyperoxaluria

ABSTRACT

Primary hyperoxaluria is a rare congenital autosomal recessive disorder disrupting the glyoxylate metabolism pathway in the liver. Type1 primary hyperoxaluria is caused by a deficiency in a specific liver enzyme namely, alanine glyoxylate-aminotransferase which catalyzes the conversion of glyoxylate to glycine. By the absence of this enzyme, glyoxylate is converted to oxalate and high oxalate level causes deposition of insoluble calcium oxalate crystals in different organs specifically kidneys. The disease usually manifested by recurrent nephrolithiasis and/or nephrocalcinosis leads to renal failure. This report describes an end-stage renal disease case of a 36-year-old Iranian woman without any history of nephrolithiasis who underwent kidney transplantation. She developed an early onset transplant kidney failure. The patient underwent kidney biopsy, which revealed oxalate nephropathy, accordingly the genetic study confirmed diagnosis of primary hyperoxaluria. This rare case shows how type 1 primary hyperoxaluria can develop after kidney transplantation without having any manifestation prior to transplantation

Implication for health policy/practice/research/medical education:

Type 1 primary hyperoxaluria is a situation in which due to specific enzyme deficiency, the Oxalate amount of blood increases and causes recurrent nephrolithiasis and/or nephrocalcinosis which can progress toward renal failure. In this report we describe a case without any history of nephrolithiasis who underwent kidney transplantation and developed transplant kidney failure due to new onset primary hyperoxaluria.

Please cite this paper as: Alirezaei A, Ebrahimibagha H, Parvin M, Ali Asgari M, Bagheri L. Late onset primary hyperoxaluria after kidney transplantation in a 36-year-old woman. J Nephrologist. 2022;x(x):e17130. DOI: 10.34172/jnp.2022.17130.

Introduction

Primary hyperoxaluria is a rare congenital disorder in glyoxylate metabolism and it is classified based on the kind of deficiency. Primary hyperoxaluria is categorized into three main different types that all of which inherited in autosomal recessive manner (1). In most cases, the affected patients are children or young adults (2). Type one of primary hyperoxaluria is the most common type and form approximately 70% of cases. It is determined by a mutation in *AGXT* gene which codes alanine glyoxylate aminotransferase (AGT) in hepatocytes. The mutations are most of the time c.508G>A (p.Gly170Arg) or c.454T>A (p.Phe152Ile) that are pathologic for

type1 primary hyperoxaluria (3). In type 1 primary hyperoxaluria, due to the enzyme deficiency, glyoxylate converted to oxalate, causing high level of oxalate excretion by kidneys. Subsequently, the kidneys become prone to recurrent urolithiasis and nephrocalcinosis. Over time, due to prolonged inflammation and fibrosis of renal parenchyma, kidney impairment progress to end-stage renal disease (ESRD). At this stage, due to negligible clearance of oxalate, blood concentration increases more and more, which is called oxalosis, causing deposition of the calcium oxalate crystals into different parts of the body including bone, retina, skin, vessels, and even central nervous system (4,5). Regarding other types of primary

*Corresponding author: Leyla Bagheri, Email: Leylabagheri90@gmail.com, L.Bagheri@sbmu.ac.ir

hyperoxaluria, in type two of PH, there are defects in the gene which encoded glyoxylate reductase/D-glycerate dehydrogenase. The presentation of the disease is mild in comparison to type one since this type rarely progresses to ESRD. In type three of primary hyperoxaluria, the defect attributed to 4-hydroxy-2-oxoglutarate aldolase (*HOGA1*) gene which encoded 4-hydroxy-2-oxoglutarate aldolase enzyme, involving in hydroxyproline metabolism. The presentation starts early in life with nephrolithiasis, however there are not recurrent episodes of nephrolithiasis and eventually it will not progress toward ESRD.

Case Presentation

A 36-year-old woman presented to our hospital in October 2019. She was a diagnosed case of ESRD caused by hypertension. The patient was on hemodialysis by a permanent catheter for five months before presentation. The patient had no history of diabetics, nephrolithiasis or any prior surgery since her family history for renal stone was negative. In the physical exam, she had no remarkable note except pallor of the conjunctiva. Her laboratory tests revealed serum creatinine; 9.45 mg/dL, urea; 84 mg/dL and a hemoglobin level of 10.9 g/dL. The patient underwent kidney transplantation from an Iranian non-related living donor. Then she was treated with prednisolone, mycophenolate mofetil, and tacrolimus. On the second day after surgery, the patient's serum creatinine decreased to 1.4 mg/dL. During the seventh day post-operation, her serum creatinine started rising and reached 1.8 mg/dL. Color Doppler ultrasonography of transplant kidney was unremarkable. Therefore, a kidney biopsy was conducted. In light microscopy study, glomeruli showed no basement membrane thickening or sclerosis; however, tubular epithelial damage regarding increased intra-tubular calcium oxalate crystals was noted. Additionally, no significant tubular atrophy or interstitial fibrosis was seen. Totally, it was reported as acute tubular necrosis-like (ATN-like) feature in renal parenchyma, since C4d was negative. The patient was treated with intravenous (IV) fluids and immunosuppressive drugs and low-oxalate diet. Thirteenth day of post-operation led to serum creatinine enhancement up to 3.6 mg/dL. While there were not any oxalate crystals in parenchyma

in previous biopsy and since the deposition of calcium oxalate crystals was essential for the diagnosis of primary hyperoxaluria, the patient underwent another renal biopsy under ultrasonography guide. This time on the light microscopic sections, marked increased deposition of calcium oxalate in both tubules and parenchyma while epithelial cells damage was also noted. Figure 1 indicates the features of oxalate nephropathy.

Further evaluation showed uric acid of 325 mg/24 h, calcium of 25 mg/24 h in 24 hours urine collection. This test also showed Na of 192 mEq/L/24 h, citrate of 1847 mg/24 h, and oxalate of 112.5 mg/24 h (normal range; 20-60 mg) and also cystine of 16.6 μ mol/d. After excluding the other cause of hyperoxaluria such as dietary cause, enteric cause, and massive exposure to oxalate precursors, molecular genetic test was carried out which illustrated in Table 1. Then, the patient was discharged with serum creatinine of 3 mg/dL with the final diagnosis of type one primary hyperoxaluria with a good general condition.

Discussion

Primary hyperoxaluria is an autosomal recessive disorder in glyoxylate metabolism causing high level of oxalate in the blood and subsequently deposition of oxalate crystals in different organs especially kidneys. Recurrent nephrolithiasis is a prominent feature of the disease which leads to ESRD. In this situation, oxalate will not excrete by kidneys. With overproducing oxalate by the liver, its level increases enormously then various complications may occur (3). We present an adult woman with primary hyperoxaluria who became symptomatic just after kidney transplantation.

Kim et al reported a case of a 43-year-old woman who did not have any history of urolithiasis and nephrocalcinosis; however, four days after kidney transplantation surgery her creatinine elevated, suggesting acute rejection. When the renal biopsy was performed, there was no evidence of rejection, however deposition of calcium crystals in tubules was evident. In her urine sample, high level of oxalate was detected. After a few months, due to deterioration of the renal function, hemodialysis was started again. Then liver biopsy detected very low activity of AGT (6). AGT is found in the hepatocytes and the

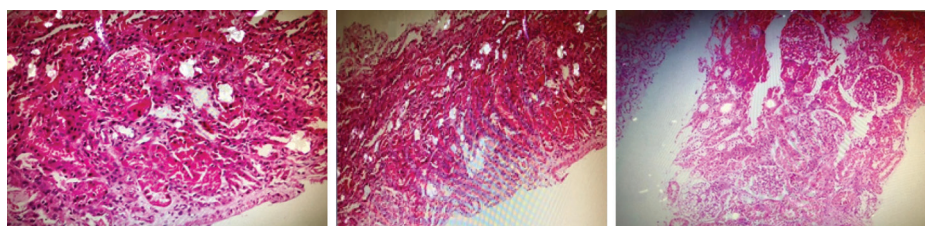


Figure 1. Calcium oxalate crystals are seen in both tubules and parenchyma (H&E staining, second renal biopsy \times 400 and \times 200).

Table 1. Results of molecular genetic test, Sanger sequencing for all exons of *AGXT* gene

Gene Transcript	Variant Position	Variant	Chromosome position	Zygoty	Inheritance	Classification
<i>AGXT</i> (NM_000030)	Ex1	c.32C>T p. P11L	chr2:241808314C>T	HOM	AR	Benign
	Ex5	c.584T>G p. M195R	chr2:241812455T>G	HOM	AR	VUS
	Ex10	c.1020A>G p.1340M	chr2:2418175116A>G	HOM	AR	Benign

HOM: homozygote, AR: Autosomal Recessive, VUS: variant of uncertain significance.

pathologic mutations of type one primary hyperoxaluria reduces the activity of this enzyme. Therefore, logically measurement of catalytic activity of this enzyme by taking a liver biopsy is considered as a reliable diagnostic test (5). Our patient was not presented any sign or symptom of hyperoxaluria while after the kidney transplantation the complication of the disease became evident by transplant kidney dysfunction.

Recently Cai et al presented three cases. One of them was a 27-year-old man with a history of nephrolithiasis who underwent kidney transplantation and due to delayed graft function, a kidney biopsy was performed on the day 46 post-renal transplantation that showed acute T cell mediated rejection and calcium oxalate crystals deposition. Molecular genetic testing detected mutation in the gene *GRHPR* which was diagnosed as a type 2 of primary hyperoxaluria. Another case was a 26-year-old man who underwent kidney transplantation similarly, due to delayed graft function, a kidney biopsy was conducted which calcium oxalate deposition was detected. Additionally, genetic testing confirmed type 1 primary hyperoxaluria. The other case was a 34-year-old man with similar condition whose disease was not proven by genetic testing (1). In the previous case, it was unveiled that patients with primary hyperoxaluria can either have or do not have the history of oxalosis such as urolithiasis. However, obviously the lack of presence of such history of oxalosis may deviate the physicians during primary evaluations. It should be mentioned that renal failure takes over times to develop. the creatinine level in our case started rising on the seventh day post-transplantation while in some cases it took months for starting the manifestation.

In our case, the molecular genetic testing determined tree minor variants: *p.P11L* in exon1, *p.M195R* in exon5, and *p.1340M* in exon10. Among these variants, *p.M195R* is known pathogenic for PH1 and *p.P11L* is considered to be a minor allele (3, 5). Minor alleles do not cause the disease by themselves however, they can intensify the destructive effects of major alleles (5). The other pathologic variants reviewed by Milliner et al are *c.508G>A* (p.Gly170Arg) and *c.454T>A* (p.Phe152Ile) (3).

Conclusion

Based on the genetic tests, neither liver biopsy nor measurement of enzyme level in the hepatocytes was needed when we have a known case of ESRD due to primary hyperoxaluria. It is possible to conduct both kidney and liver transplantation to prevent the relapse of the disease and to prevent transplant kidney failure, as mentioned in most studies. However in the setting of our case, when we do not have any clue suggesting primary hyperoxaluria, it is inevitable to detect the disease after kidney transplantation; since the deposition of calcium oxalate crystals in the transplant kidney is the first sign of the disease. That is why we called the condition late onset primary hyperoxaluria.

Authors' contribution

AA, LB and MA treated and followed the patient and revisited the case. MP was the pathologist of the case who did the microscopy and reported pathology. HE gathered all the data and wrote the draft with the help of LB and AA. All the authors read and signed the final paper.

Conflicts of interest

There is no conflict of interest in this study.

Ethical considerations

Ethical issues including plagiarism, double publication, and redundancy have been completely observed by the author. The patient gave the consent to publish as a case report.

Funding/Support

None.

References

1. Cai R, Lin M, Chen Z, et al. Primary hyperoxaluria diagnosed after kidney transplantation failure: lesson from 3 case reports and literature review. *BMC Nephrol.* 2019;20:224. doi: 10.1186/s12882-019-1402-2
2. Riksen NP, Timmers HJ, Assmann KJ, Huysmans FT. Renal graft failure due to type 1 primary hyperoxaluria. *Neth J Med.* 2002;60:407-410.

3. Milliner DS, Harris PC, Cogal AG, Lieske JC. Primary Hyperoxaluria Type 1. In: Adam MP, Ardinger HH, Pagon RA, eds. GeneReviews®. Seattle (WA): University of Washington, Seattle; 1993.
4. Spasovski G, Beck B, Blau N, Hoppe B, Tasic V. Late diagnosis of primary hyperoxaluria after failed kidney transplantation. *Int Urol Nephrol*, 2010;42:825-9.
5. Harambat J, Fargue S, Bacchetta J, Acquaviva C, Cochat P. Primary hyperoxaluria. *Int J Nephrol*. 2011;2011:864580. doi:10.4061/2011/864580
6. Kim H, Koh H, Ku B, Lee H. Late-onset primary hyperoxaluria diagnosed after renal transplantation presented with early recurrence of disease. *Nephrol Dial Transplant*. 2005;20:1738-40.
7. Çelik G, Sen S, Sipahi S, Akkin C, Tamsel S, Töz H ,et al. Regressive course of oxalate deposition in primary hyperoxaluria after kidney transplantation. *Ren Fail*. 2010; 32:1131-1136.

Copyright © 2021 The Author(s); Published by Society of Diabetic Nephropathy Prevention. This is an open-access article distributed under the terms of the Creative Commons Attribution License (<http://creativecommons.org/licenses/by/4.0>), which permits unrestricted use, distribution, and reproduction in any medium, provided the original work is properly cited.