

Journal of Nephrologist



Role of the scrotal color Doppler ultrasound findings in management of severe orchitis to do orchiectomy

Seyed Morteza Bagheri¹, Morteza Mohammad Mirzaei, Tohid Mousavian, Mostafa Ghadamzadeh^{*1}

Department of Radiology, Hasheminejad Kidney Center (HKC), Iran University of Medical Sciences, Tehran, Iran

ARTICLE INFO

Article type:
Original Article

Article history:
Received: 2 February 2020
Accepted: 20 October 2020
Published online: 4 December 2020

Keywords:
Epididymo-orchitis
Color Doppler ultrasonography
Resistance index

ABSTRACT

Background: Introduction: Determination of the type of treatment and prognosis of epididymo-orchitis is a challenge for clinicians.

Objectives: The current study aimed at investigating the relationship between the indexes of vascular resistance index (RI) (%) of the intra-testicular artery by color Doppler ultrasonography (CDUS), and its relationship with the treatment and prognosis in patients with epididymo-orchitis.

Patients and Methods: The current prospective observational study was conducted on the collected data of 30 patients with epididymo-orchitis. Initial and secondary CDUS (24 hours after admission) were conducted on all patients and RI was calculated from the mean of two intratesticular arteries for all patients. Patients were divided into four groups based on RI through, RI; 70-80%, RI; 80-90%, RI >90%, and absent of flow.

Results: The mean and standard deviation (SD) of the patients' age was 47.70 ± 15.56 years (ranged 30-79 years). Among 30 patients, 15 (50%) had left epididymo-orchitis, 13 (43.5%) right, and in two subjects (6.71%), it was bilateral. The mean \pm SD of RI in the initial and secondary CDUS were $0.8516 \pm 0.1022\%$ and $0.7845 \pm 0.1235\%$, respectively ($P=0.031$). The ROC under area of RI diagnosis power for the types of epididymo-orchitis treatment were 0.904 [95% confidence interval (CI): 0.774-1.000] and 0.990 (95%CI: 0.958-1.000) in the initial and second day of CDUS, respectively. Additionally, the mean \pm SD of RI in initial CDUS were $0.7633 \pm 0.03786\%$, $0.84400 \pm 0.02944\%$, and $0.7600 \pm 0.03162\%$ in patients with a decreased prognosis, atrophy, and parenchymal heterogeneity, which were significantly different ($P=0.011$). Accordingly, in the CDUS of 24 hours after admission, the mean \pm SD of RI in patients with low prognosis was $0.6600 \pm 0.0100\%$, in patients with atrophy was $0.0170 \pm 0.7575\%$, and in patients with parenchymal heterogeneity was $0.7100 \pm 0.04729\%$.

Conclusion: RI of intratesticular artery in CDUS is a useful index to determine and predict the type of treatment and prognosis of patients with epididymo-orchitis.

Implication for health policy/practice/research/medical education:

Vascular resistance of intra-testicular artery in color Doppler ultrasonography is an appropriate index for prediction of the prognosis of patients with epididymo-orchitis.

Please cite this paper as: Bagheri SM, Mohammad Mirzaei M, Mousavian T, Ghadamzadeh M. Role of the scrotal color Doppler ultrasound findings in management of severe orchitis to do orchiectomy. J Nephrologist. 2022;x(x):e17153. DOI: 10.34172/jnp.2022.17153.

Introduction

Epididymitis is an inflammatory process of the epididymis that can have infectious or non-infectious etiology. Epididymitis with testicular involvement is called epididymo-orchitis. This disease is a common urologic pathology in males that presents with pain and scrotal swelling. Unfortunately, there is no accurate statistic

of the prevalence of epididymo-orchitis since there are differences between published reports (1,2) regarding bacterial and viral infection, trauma, autoimmune disorder, amiodarone use, surgical manipulation, bladder outlet obstruction, or any other urogenital malformations. Since this disease requires rapid therapeutic intervention, it should be differentially diagnosed from a variety of

***Corresponding author:** Mostafa Ghadamzadeh,
Email: Ghadamzadeh.m@iums.ac.ir

conditions such as torsion of the testicles. Timely and correct diagnosis of such patients is one of the most important factors in clinical management (3). Diagnostic process consists of history and physical examination, laboratory and imaging, and microbiological analysis (4). Since the physical examination and clinical features of scrotal diseases is nonspecific, the diagnosis of scrotal diseases was always a challenge for the clinicians. Therefore, the role of imaging is of great importance in the diagnosis of scrotal diseases (5). Color Doppler ultrasound is the method of choice to evaluate vascularity of various organs such as the testis. This imaging method is employed to examine the blood flow in the testis artery and to diagnose testicular pathology related to change in blood flow. This technique can differentiate torsion of spermatic cord from epididymo-orchitis (6). Some other advantages of this imaging are absence of radioactive radiation, frequent use, availability and being painless, non-invasive and inexpensive (7). Studies show that the resistance index (RI), or the index of intra-scrotal artery, provides a more objective assessment of the *increased flow* in intra-scrotal inflammation and has higher diagnostic accuracy (8). Additionally, testicular tissue is one of the organs with a low vascular resistance (RI) (<0.70) even during the typical orchitis. Due to the existence of a thick and rigid structure of tunica albuginea around the testis, if inflammatory changes are caused by severe orchitis, then the pressure increases within the testicular parenchymal and, thus, increases the RI of intratesticular artery.

Objectives

Since no comprehensive study is conducted on the role of Doppler ultrasonography and RI in the prognosis of the epididymo-orchitis, the current study aimed at investigating the Doppler findings in epididymo-orchitis and its relationship with the treatment and prognosis of the disease.

Materials and Methods

Study population

The current prospective, observational study was conducted on patients with a primary complaint of pain and swelling (or combination of the symptoms) of the scrotum referring to the Hasheminejad kidney center, Tehran, Iran, from January 2017 to January 2018. The study population included the patients with scrotal pain diagnosed with epididymo-orchitis who were referred to color Doppler ultrasonography (CDUS) unit. About 300 patients that undergone complete evaluation, patients with RI >70%, or reduced or absent flow. The exclusion criteria were; the onset of symptoms for more than 24 hours, antibiotic use over the past 72 hours, extratesticular conditions such as severe hydrocele, severe pyocele,

testicular abscess on admission, as well as cases where ultrasonography was not possible to follow, testicular atrophy, history of testicular surgery, cryptorchidism and history of torsion.

Ultrasonography examination

Complete medical history and physical examination were taken from all patients, and their characteristics were recorded in a special checklist. If necessary, laboratory tests (blood and urine culture) were performed on them. Patients were evaluated in supine position by a skilled radiologist using liner probe (5 to 12 MHz, Philips Affinity 50). The criteria to detect orchitis in gray-scale ultrasound were testicular and epididymal enlargement and edematous, thickening of the scrotum, and parenchymal hyperechogenicity. The criterion to detect orchitis in CDUS was the increase of blood flow. The RI of the testicular and epididymal arteries was calculated automatically by the ultrasound device based on the following formula;

RI: (peak systolic velocity - end diastolic velocity)/peak systolic velocity. RI was obtained from 2-3 points of relatively central parts of testicular parenchyma with an emphasis on the central areas. For statistical analysis, the mean of the values was used. Ultrasound examination was performed on patients on admission and 24 hours after the admission, then the obtained values were compared with the type of treatment and follow-up. The final diagnosis of orchitis was made based on examinations, laboratory tests, history, and imaging results, while each patient was treated according to the diagnosis (orchiectomy, oral or injectable antibiotics). Patients were followed up for treatment, complications and final outcome.

Ethical issues

The research followed the tenets of the Declaration of Helsinki. The Ethics Committee of Iran University of Medical Sciences approved this study. The institutional ethical committee at Iran University of Medical Sciences approved all study protocols (IR.IUMS.FMD.REC.1396.941). Accordingly, written informed consent was taken from all participants before any intervention. This study was extracted from M.D, thesis of Morteza Mohammad Mirzaei at this university.

Statistically analysis

The collected data were transferred into SPSS software. In the descriptive section, quantitative data were expressed as mean \pm standard deviation (SD) and qualitative data as percentages and frequency. In statistical analysis, chi-square test, independent t-test, and one-way ANOVA were used. ROC (receiver operating characteristic) curve analysis was performed using statistical tests with SPSS

version 20.0 (SPSS Inc., Chicago, IL, USA). In all cases, $P < 0.05$ was considered statistically significant.

Results

Totally, information of 30 patients was analyzed. The mean and SD of the patients' age was 47.70 ± 15.56 years (ranged 30-79). Among the 30 patients, 15 (50%) had left epididymo-orchitis, 13 (43.5%) had right, and two subjects (6.71%) were bilateral. In the initial CDUS assay, no vascular flow was observed in seven subjects (23.30%) since 23 subjects (76.7%) had flow decrease. Additionally, the mean \pm SD of RI was $0.851 \pm 0.102\%$. Patients were divided into four groups based on RI, as RI; 70-80%, RI; 80-90%, RI >90%, and absent of flow in the initial and secondary CDUS. We found, in eight (26.6%) subjects, RI range was 7%0-80%, in nine subjects (30%) RI range was 80%-90%, and in six subjects, the RI was more than 90%. In CDUS study, 24 hours after the admission (secondary), the mean \pm SD of RI was $0.7845 \pm 0.1235\%$; however, 8 (26.6%) of subjects had an RI range of 70 -80%, 9 (30%) of subjects had RI of 80-90%, since three ones had RI >90%. Totally, 19 patients (63.3%) were admitted to orchiectomy and 11 subjects (36.7%) received antibiotics. To study the correlation between clinical and CDUS findings with the type of treatment (Table 1, Figure 1) on patients with left epididymo-orchitis, the orchiectomy was performed on 10 patients (33.3%) and four patients (13.33%) only received antibiotic therapy. In right epididymo-orchitis, 8 patients (26.6%) had orchiectomy and 5 patients (16.66%) received antibiotic therapy. In bilateral type, one patient (3.33%) had orchiectomy, and one patient received antibiotics. In the initial CDUS assay and among the subjects undergoing orchiectomy, six (20%) had RI 80-90%, and six patients (20%) had

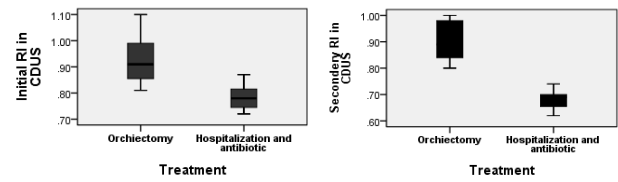


Figure 1. Mean of the initial and secondary resistance index according to type of treatment in patients with epididymo-orchitis ($P < 0.001$). CDUS, color Doppler ultrasonography.

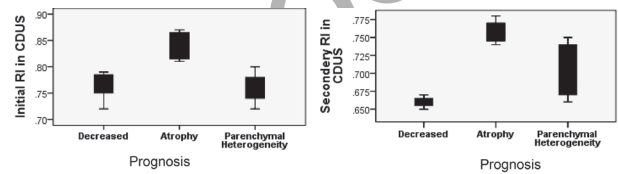


Figure 2. Mean of the initial and secondary resistance index according to type of prognosis in patients with epididymo-orchitis ($P < 0.001$). CDUS, color Doppler ultrasonography.

Table 1. Comparison of two groups (orchidectomy and hospitalization/antibiotics) by epididymo-orchitis IR category and CDUC

Variable	Treatments		P	
	Orchiectomy	Hospitalization and Antibiotics		
Epididymo-orchitis	Left	10(33.3)	4(13.33)	0.541
	Right	8(26.6)	5(16.66)	
	Bilateral	1(3.33)	1(3.33)	
Initial CDUS	Flow	0	0	0.025
	Absent	7(23.3)	0	
	Decreased	12(40)	11(36.6)	
IR category (%)	70-80	0	8(26.6)	0.001
	80-90	6(20)	3(10)	
	>90	6(20)	0	
Secondary CDUS	Flow	0	0	0.025
	Absent	7(23.3)	0	
	Decreased	12(40)	11(36.6)	
IR category (%)	70-80	0	7(23.33)	0.002
	80-90	6(20)	2(6.66)	
	>90	3(10)	0	

RI >90% ($P = 0.025$). Among the patients admitted and received only antibiotics, 8 (26.6%) had RI 70-80%, and 3 (10%) 80-90% ($P = 0.001$). After a 24-hour ultrasound examination, we found 7 subjects (23.3%) had flow absence, and 12 (40%) had flow decrease. In subjects undergoing orchiectomy, 11 patients (36.6%) had flow decrease. Additionally, in subjects with orchiectomy, 6 (20%) patients had RI 80-90%, and three (10%) had an RI >90%. In patients receiving antibiotic, seven (23.33%) had RI of 70-80% and two (6.66%) had RI of 80-90% ($P = 0.002$). In the study on the relationship between clinical findings and RI category (Table 2, Figure 2), the age parameter increased with increasing RI at the time of admission ($P = 0.441$) and 24 hours after admission ($P = 0.006$). Accordingly, no significant difference in distribution of the type of epididymo-orchitis, according to initial and secondary RI categories ($P = 0.852$ and $P = 0.462$) was detected. There was a significant correlation between the type of treatment and the increase of initial and secondary RI ($P = 0.001$ for both); since, all patients with initial RI >90% and secondary RI >80% underwent orchiectomy.

Furthermore, the mean \pm SD of RI in initial CDUS, according to prognosis, was $0.763 \pm 0.037\%$ in patients with decrease flow, $0.844 \pm 0.029\%$ in the individuals with atrophy, and $0.760 \pm 0.031\%$ in patients with parenchymal heterogeneity ($P = 0.011$). Moreover, in the CDUS 24 hours after admission, the mean \pm SD of RI in prognostic patients decreased to $0.66 \pm 0.01\%$, in subjects with atrophy was $0.017 \pm 0.757\%$, and in the individuals with parenchymal heterogeneity, it was $0.7100 \pm 0.04729\%$. In the ROC analysis, the under area of RI was

Table 2. Comparison of two groups (initial and secondary) by epididymo-orchitis and hospitalization/antibiotics

Variable	Initial RI in CDUS (%)				P	Secondary RI in CDUS (%)				P
	Absent flow	70-80	80-90	>90		Absent flow	70-80	80-90	>90	
Age (years)	43.14±7.6	48.29±16.38	48.50±16.84	55.40±17.20	0.441	42.30±6.43	47.37±12.32	54.32±33.21	66.43±11.23	0.060
Epididymo-orchitis						Epididymo-orchitis				
Left	4	2	5	3	0.852	3	6	2	2	0.462
Right	3	4	3	3		4	5	2	0	
Bilateral	0	0	2	0		0	1	1	0	
Treatment						Hospitalization and antibiotics				
Orchiectomy	7	0	6	6	0.001	7	2	5	2	0.001
Hospitalization and antibiotics						Hospitalization and antibiotics				
Prognosis	0	7	4	0	0.031	0	11	0	0	0.001
Decrease Size	0	3	0	0		0	3	0	0	
Atrophy	0	0	4	0		0	4	0	0	
Parenchymal heterogeneity	0	4	1	0		0	5	0	0	

RI, resistance index; CDUS, color Doppler ultrasonography

Table 3. AUC of CDUS for initial and secondary RI

Variable	AUC	95% Confidence interval		P value
		Lower bound	Upper bound	
Initial RI in CDUS	0.904	0.774	1.000	0.002
Secondary RI in CDUS	0.990	0.958	1.000	0.000

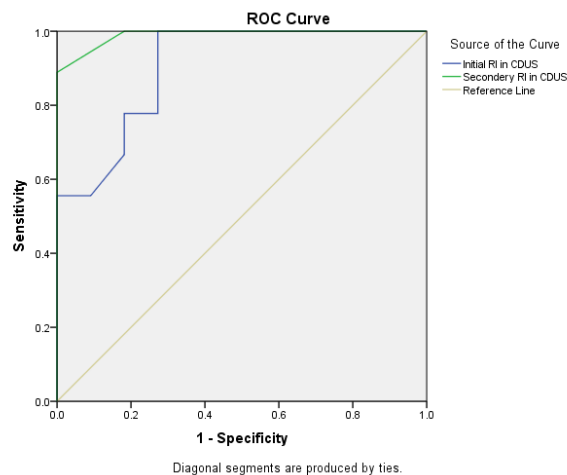
RI, resistance index; CDUS, color Doppler ultrasonography.

used to predict the type of treatment. In the initial CDUS, area under curve was 0.904 (95% CI: 0.774-1.000), and for the secondary CDUS ultrasound, it was 0.990 (95% CI: 0.958-1.000) Obtained. In addition, with a cutoff point of 0.73 for RI in the initial CDUS, a sensitivity of 100% and specificity of 81% for the diagnosis of the type of treatment was detected, respectively (Table 3, Figure 3).

Discussion

Since clinical signs and symptoms are nonspecific, the timely diagnosis of the disease is a challenging issue for clinicians. Extensive research demonstrates the importance of CDUS as a useful tool to diagnose epididymo-orchitis (10). CDUS can examine the vasculature and disease associated changes in blood flow of various organs such as the testis (11). The current study aimed to investigate the diagnostic power of CDUS and the relationship between RI with treatment type and acute complications such as orchiectomy and abscess formation and long-term complications such as parenchymal atrophy in 30 patients with epididymo-orchitis. The mean age of patients was 47.70 years, ranged 30-76; 50% of patients had left epididymo-orchitis, 43.5% right, and only 6.71% had bilateral type. The total mean of RI in patients was 0.8516 ± 0.1022 % at the initial CDUS and 0.7845 ± 0.1235 % in second day CDUS. Among the 30 patients, 63.3% were under orchiectomy. Accordingly, the current study

findings showed a significant relationship between the type of treatment and mean RI. The mean RI in initial CDUS respectively was 0.9233 ± 0.08763 % and 0.9873 ± 0.0521 % in patients undergoing orchiectomy and a patient only receiving antibiotic therapy ($P = 0.001$). The mean RI in the secondary CDUS was 0.8633 ± 0.08170 % and 0.6982 ± 0.03970 % in patients undergoing orchiectomy and antibiotic therapy, which were significantly different ($P = 0.001$). To date, most studies are conducted on

**Figure 3.** ROC (receiver operating characteristic) analysis and AUC (area under the curve) for initial and secondary CDUS by the treatment

Doppler's efficacy to diagnose epididymo-orchitis; since for the first time, the current study reported the relationship between RI and incidence of orchiectomy in patients with epididymo-orchitis. Studies show that RI <0.5% can be indicative of healthy vascular status compared with the orchitis. Besides, high levels of RI can be indicative of an ischemia caused by an outflow vessel blocking while this condition is a medical emergency status, which requires surgical intervention (12,13). The current study also indicated that patients with a higher RI were more likely to have undergone orchiectomy, and patients with lower RI were hospitalized and did not require surgery. However, some studies reported that the RI in the testicular artery is less in patients with epididymo-orchitis than a patient with epididymitis alone, and in healthy subjects (14). This difference is attributed to the high blood flow of the epidermal arteries; particularly the testicular artery (15). In addition, the current study used the mean RI of the intratesticular artery. The current study also showed that the RI in the initial CDUS with a cutoff point of 0.73 and in the second day CDUS with a cutoff point of 0.63 had the highest sensitivity and specificity for the type of treatment. Most studies are conducted on the ability of CDUS to diagnose and differentiate orchitis from other inflammatory and ischemic diseases of scrotum such as neoplasia and torsion (16). The current study was the first to investigate the relationship between intratesticular RI in CDUS with the incidence of orchiectomy and prognosis of patients with epididymo-orchitis. This method is very fast and non-invasive with a diagnostic power equal to the other diagnostic methods such as a nuclear scan. This method can also differentiate the vascular flow of the scrotal wall from the intra-testicular vessels. The advantage of this imaging method, compared with other methods, is that it can be easily performed without wasting time (17,18).

Conclusion

The current study included limitations such as the small sample size and lack of examination of the RI diagnostic power to differentially diagnose orchitis from torsion. According to the results of the current study, it can be concluded that the RI achieved by CDUS can be a strong predictor of the type of treatment and prognosis of patients with epididymo-orchitis.

Acknowledgements

This study was taken from residential thesis with code 78. The authors would like to thank the deputy of the research of Iran University of Medical Sciences; all the honorable patients participated in the research, and all those who were very cooperative in this study.

Limitations of the study

The main limitation in this observational study was small sample size conducted from January 2017 to January 2018. It is suggested to consider longtime follow up to obtain larger sample size.

Authors' contribution

SMB, MMM and TM were the principal investigators of the study. MG, TM, SMB and MMM were included in preparing the concept and design. SMB and MG revised the manuscript and critically evaluated the intellectual contents. All authors participated in preparing the final draft of the manuscript, revised the manuscript and critically evaluated the intellectual contents. All authors have read and approved the content of the manuscript and confirmed the accuracy or integrity of any part of the work.

Conflicts of interest

The authors declared no competing interests.

Ethical considerations

Ethical issues (including plagiarism, data fabrication, double publication) have been completely observed by the authors.

Funding/support

This study was taken from M.D, thesis of Morteza Mohammad Mirzaei (Thesis #78) and supported by research deputy of Iran University of Medical Sciences.

References

1. Simms I, Fleming DM, Lowndes CM, Smith GE, Chapman RS. Surveillance of sexually transmitted diseases in general practice: a description of trends in the Royal College of General Practitioners Weekly Returns Service between 1994 and 2001. *Int J STD AIDS*. 2006;17:693-8. doi: 10.1258/095646206780070992.
2. Collins MM, Stafford RS, O'Leary MP, Barry MJ. How common is prostatitis? A national survey of physician visits. *J Urol*. 1998;159:1224-1228.
3. Horner PJ. European guideline for the management of epididymo-orchitis and syndromic management of acute scrotal swelling. *Int J STD AIDS*. 2001;12:88-93. doi: 10.1258/0956462011924010
4. Garthwaite MA, Johnson G, Lloyd S, Eardley I. The implementation of European Association of Urology guidelines in the management of acute epididymo-orchitis. *Ann R Coll Surg Engl* 2007;89:799-803. doi: 10.1308/003588407X232026
5. Lerner RM, Mevorach RA, Hulbert WC, Rabinowitz R. Color Doppler US in the evaluation of acute scrotal disease. *Radiology*. 1990;176:355-8. doi: 10.1148/radiology.176.2.2195590

6. Dubinsky T, Chen P, Maklad N. Color-flow and power Doppler imaging of the testes. *World J Urol* 1998; 16:35-40.
7. Morais RH, Muglia VF, Mamere AE, Pisi TG, Saber LT, Muglia VA, et al. Duplex Doppler sonography of transplant renal artery stenosis. *J Clin Ultrasound*. 2003; 31(3):135-41.
8. Jee WH, Choe BY, Byun JY, Shinn KS, Hwang TK. Resistive index of the intrascrotal artery in scrotal inflammatory disease. *Acta Radiol*. 1997;38:1026-30. doi: 10.1080/02841859709172124.
9. Mernagh JR, Caco C, De Maria J. Testicular torsion revisited. *Curr Probl Diagn Radiol*. 2004;33(2):60-73. 2004;33:60-73.
10. Sidhu PS. Clinical and imaging features of testicular torsion: role of ultrasound. *Clin Radiol*. 1999;54:343-52.
11. Sriprasad S, Kooiman GG, Muir GH, Sidhu PS. Acute segmental testicular infarction: differentiation from tumour using high frequency colour Doppler ultrasound. *Brit J Radiol*. 2001;74:965-7. doi: 10.1259/bjr.74.886.740965
12. Lefort C, Thoumas D, Badachi Y, Gobet F, Pfister C, Dacher JN, et al. Ischemic orchiditis: review of 5 cases diagnosed by color Doppler ultrasonography. *J Radiol* 2001;82:839-42.
13. Dogra VS, Rubens DJ, Gottlieb RH, Bhatt S. Torsion and beyond: new twists in spectral Doppler evaluation of the scrotum. *J Ultrasound Med* 2004;23:1077-85.
14. Jee WH, Choe BY, Byun JY, Shinn KS, Hwang TK. Resistive index of the intrascrotal artery in scrotal inflammatory disease. *Acta Radiol*. 1997; 38:1026-30.
15. Middleton WD, Thorne DA, Melson GL. Color Doppler ultrasound of the normal testis. *AJR Am J Roentgenol*. 1989;152:293-7. doi: 10.2214/ajr.152.2.293.
16. Rizvi SA, Ahmad I, Siddiqui MA, Zaheer S, Ahmad K. Role of color Doppler ultrasonography in evaluation of scrotal swellings: pattern of disease in 120 patients with review of literature. *Urol J*. 2011;8(1):60-5.
17. Ludwig M. Diagnosis and therapy of acute prostatitis, epididymitis and orchitis. *Andrologia*. 2008;40(2):76-80. doi: 10.1111/j.1439-0272.2007.00823.x.
18. Pepe P, Panella P, Pennisi M, Aragona F. Does color Doppler sonography improve the clinic assessment of patients with acute scrotum? *Eur J Radiol* 2006; 60:120-4. doi: 10.1016/j.ejrad.2006.04.016

Copyright © 2021 The Author(s); Published by Society of Diabetic Nephropathy Prevention. This is an open-access article distributed under the terms of the Creative Commons Attribution License (<http://creativecommons.org/licenses/by/4.0>), which permits unrestricted use, distribution, and reproduction in any medium, provided the original work is properly cited.