

Journal of Nephrothology



Ameliorative impact of hydroalcoholic extract of Clove buds (*Syzygium aromaticum*) on contrast-induced acute kidney injury; an experimental histopathological study

Parto Nasri¹, Niloufar Hooshyar², Banafsheh Yalameha³, Mahsa Akafzadeh Savari⁴, Mohammadreza Khosravifarsani⁵, Saied Mardani⁶, Pegah Noorshargh⁷, Ali Hasanpour Dehkordi⁸, Hamid Nasri^{4,9*}, Elnaz Golestaneh¹⁰, Elham Bijad¹¹, Behzad Ghasemi¹², Nafiseh Nowrouzi¹²

¹Infectious Diseases and Tropical Medicine Research Center, Isfahan University of Medical Sciences, Isfahan, Iran

²Faculty of Medicine, Isfahan University of Medical Sciences, Isfahan, Iran

³Department of Biochemistry, Faculty of Medicine, Lorestan University of Medical Sciences, Khorramabad, Iran

⁴Nickan Research Institute, Isfahan, Iran

⁵Cancer Prevention Research Center, Isfahan University of Medical Sciences, Isfahan, Iran

⁶Department of Internal Medicine, Medicine Faculty, Shahrekord University of Medical Sciences, Shahrekord, Iran

⁷Alzahra Research Institute, Isfahan University of Medical Sciences, Isfahan, Iran

⁸Social Determinants of Health Research Center, Shahrekord University of Medical Sciences, Shahrekord, Iran

⁹Department of Internal Medicine, Isfahan, University of Medical Sciences, Isfahan, Iran

¹⁰Faculty of Pharmacy, Isfahan University of Medical Sciences, Isfahan, Iran

¹¹Medical Plants Research Center, Basic Health Sciences Institute, Shahrekord University of Medical Sciences, Shahrekord, Iran

¹²Faculty of Pharmacy, University of Pécs, Pécs, Hungary

ARTICLE INFO

Article type:
Original Article

Article history:
Received: 11 June 2019
Accepted: 8 September 2019
Published online: 3 October 2019

Keywords:
Clove buds
Syzygium aromaticum
Acute kidney injury
Iodinated contrast media
Reactive oxygen species

ABSTRACT

Introduction: The administration of iodinated contrast medium is extensive in various imaging techniques including coronary angiography.

Objectives: The present investigation was designed to examine the ameliorative effect of clove buds (*Syzygium aromaticum*) on contrast-induced acute kidney injury (CI-AKI) in rats

Materials and Methods: Forty male Wistar rats with a mean body weight of 200-250 g were studied. Rats randomly assigned into four groups, 10 rats for each; Group 1; normal rats (control group; sham group); they did not receive any drugs. Group 2; rats were received 10 mL/kg as a single dose of iodixanol (contrast media) by intravenous (IV) injection. Group 3; rats received 10 mg/kg clove by intraperitoneal (IP) injection for three days, while in day forth, they received a single dose of iodixanol (10 mL/kg). Group 4; rats of this group first received a single dose of iodixanol (10 mL/kg). Then rats treated by clove (10 mg/kg) by intraperitoneal (IP) injection for three days (days 2, 3 and 4th). Kidney sections were examined for degeneration, flattening, and necrosis of renal tubular cells and also dilatation of tubular lumen.

Results: We found a significant difference between groups regarding the sum of injury (degeneration, flattening, necrosis and dilatation). A significant difference in types of injury (degeneration, flattening, necrosis and dilatation) among the groups ($P=0.001$) was seen too. We detected a significant difference between groups II (contrast media) and III (rats pretreated by clove; $P<0.001$). Accordingly, we detected a significant difference between groups II (contrast media) and IV (rats post-pone treated by Clove buds; $P<0.001$) too. There was not a significant difference between groups of III and IV ($P>0.05$).

Conclusion: In this animal study, we found that post-pone treatment of clove was as effective as pre-treatment to mitigate the injury induced by contrast media.

Implication for health policy/practice/research/medical education:

In an experimental study, we found that post-pone treatment of clove was also effective to mitigate the renal injury induced by contrast media.

Please cite this paper as: Nasri P, Hooshyar N, Yalameha B, Akafzadeh Savari M, Khosravifarsani MR, Mardani SM, et al. Ameliorative impact of hydroalcoholic extract of Clove buds (*Syzygium aromaticum*) on contrast-induced acute kidney injury; an experimental histopathological study. J Nephrothol. 2022;x(x):e9816. DOI: 10.15171/jnp.2022.9816.

*Corresponding author: Prof. Hamid Nasri, Email; hamidnasri@med.mui.ac.ir

Introduction

Nowadays, the administration of iodinated contrast medium is extensive in different imaging techniques including coronary angiography. It has demonstrated that the administration of iodinated contrast media is correlated with different complications including acute kidney injury (AKI) and other renal disorders. Contrast-induced acute kidney injury (CI-AKI) is detected as one of the leading causes of hospital-acquired acute renal failure. CI-AKI is related to a sharp decline in kidney function and increases morbidity, early mortality, and hospital stay in the general population exposure to contrast agent (1-3).

The various risk factors are known for CI-AKI such as hypotension, heart failure, anemia, renal disease, diabetes mellitus, nephrotoxic medications, and extra. One of the important factors involved in the development of CI-AKI is the oxidative stress process. Oxidative stress refers to the imbalance between reactive oxygen species (ROS) and the body's antioxidant system in favor of ROS and free radicals (4).

Several findings have confirmed that the administration of contrast medium is involved in the occurrence of the renal hypoxia and elevates further ischemic renal injury through generating ROS including peroxides, superoxide anions, and hydroxyl radicals during the oxidative stress process (5). Additionally, contrast agent stimulated renal vasoconstriction and mitochondrial dysfunction (6). In recent years, many therapeutic strategies have been suggested for the improvement of renal failure due to the contrast medium and intravenous hydration method applied widely for patients exposed to CI-AKI (7). Recently, the use of different antioxidants in the treatment of disorders due to oxidative stress has become one of the most important and popular research among researchers. Therefore, it is well-known that ascorbate, as a non-proteinaceous antioxidant, has useful therapeutic effects against human renal injury and nephrotoxicity via diminishing ROS (8). N-acetylcysteine (NAC), as an antioxidant, possess lucrative effects in amelioration of CI-AKI by neutralizing free radicals and increasing glutathione synthesis (9). Furthermore, diverse medicinal plants are being used in the treatment of CI-AKI due to their antioxidant capacity that clove is one of these plants. The clove plant (*S. aromaticum*), as a food preservative, belongs to the family Myrtaceae that is exerted for multiple therapeutic purposes all over the world (10).

Numerous beneficial compounds are expressed for Clove that can be referred to eugenol, eugenyl acetate, gallic acid, β -caryophyllene, 2-heptanone, humulenol, α -humulene, and others. The finding acquired from some studies represented that clove contains the fundamental therapeutic properties such as antibacterial, antifungal, antiviral, antifungal, anti-parasitic, anti-vomiting, anti-

inflammatory, antispasmodic, anti-mutagenic, and antioxidant. It is recognized that the nephroprotective impact of clove, as a potent antioxidant, is the result of eliminating a variety of free radicals and metal chelating potency (11,12).

Objectives

The present investigation was designed to examine the ameliorative effect of clove buds (*S. aromaticum*) on CI-AKI in rats.

Materials and Methods

Plant material and extraction

Dried clove buds (*S. aromaticum*) were prepared from a local herb market in Shahrekord and were identified by local herbologist of the center. We used iodixanol as the contrast media. To prepare the extract of the clove buds, at first clove powdered and then 250 g of clove powder macerated in aqueous ethanol 70% (v/v) for 72 hours at room temperature with intermittent shaking. The macerated mixture was filtered through Whatman filter paper. Afterward, mixture concentrated using rotary evaporator (RE 100 Bibby, Stone Staffordshire England, ST15 OSA) at 50°C and dried in a laminar hood to remove residual moisture. Finally, the extracts were stored at -20°C until used.

Animals and study design

Forty male Wistar rats with a mean body weight of 200-250 g in the Medical Plants Research Center in Shahrekord University of Medical Sciences were studied. All animals were kept in normal laboratory conditions (temperature; 21-25°C and light cycle; 12 h dark-12 h light). Rats randomly assigned into four groups, 10 rats for each; Group 1; normal rats (control group; sham group); they did not receive any drugs.

Group 2; rats were received 10 ml/kg as a single dose of iodixanol (contrast media) by intravenous (IV) injection. Group 3; rats received 10 mg/kg clove by intraperitoneal (IP) injection for three days, while in day forth, they received a single dose of iodixanol (10 ml/kg).

Group 4; rats of this group first received a single dose of iodixanol (10 mL/kg), then rats treated by clove (10 mg/kg) by intraperitoneal (IP) injection for three days (days 2, 3 and 4th).

Histopathological study

The kidneys were removed immediately after sacrificing and fixing with 10% formalin for morphological study. Then, 3 μ m-thick sections of renal tissues were prepared and stained with hematoxylin and eosin (H&E) for pathological evaluation. Kidney sections were examined by a light microscope for intensity of kidney damage by

examination for degeneration, flattening and necrosis of renal tubular cells and also dilatation of tubular lumen. The slides were coded and examined by a nephropathologist who was blinded to the animal groups. The morphologic lesions were presented as the mean percent for each morphologic variable. For comparing the morphologic variables of degeneration, flattening, necrosis and dilatation between the groups, we used a sum of four morphologic variables as a total injury.

Ethical issues

All experimental protocols and steps of the tests were conducted in compliance with the regulations of the Research Ethics Committee of Iranian Ethical Guidelines for the use of animals in research. Additionally, all animal experiments were in accordance with protocols approved by the United States National Institutes of Health (NIH, 1978). This study was also approved and supported by Ethics Committee of National Institute for Medical Research Development (NIMAD; <http://nimad.ac.ir/>), Iran (#963554).

Statistical analysis

All parameters were summarized with mean and standard deviation. One-way analysis of variance (ANOVA) and post hoc tests (Bonferroni test) were used for the comparison of mean values between groups. *P* values of less than 0.05 were assumed to be significant ($P < 0.05$). To calculate sample size and data analysis SPSS version 21.0 software was used.

Results

Table 1 shows mean \pm SD of the sum of the morphologic variables of injury (degeneration, flattening, necrosis, and dilatation) in each group. As this table shows, we found a significant difference between groups ($P = 0.001$; one-way ANOVA). Table 2 shows a significant difference in various types of injury (degeneration, flattening, necrosis, and dilatation) among the groups too ($P = 0.001$; one-way ANOVA). Table 3 shows a significant difference between three groups of II, III and IV ($P < 0.001$; Bonferroni

Table 1. Mean \pm SD of the sum of injury (degeneration, flattening, necrosis, and dilatation) in each group

Groups	Sum of injury	
	Mean	SD
Control	1.7	1.25
Contrast media	87.20	20.67
Clove + contrast media	25.60	4.67
Contrast media + clove	17.80	3.74
Total	33.08	34.42
F (ANOVA)	120.614	
<i>P</i> value	0.001	

test). We found a significant difference between groups II (contrast media) and III (rats pretreated by clove buds) ($P < 0.001$). Accordingly, we detected a significant difference between groups II (contrast media) and IV (rats post-pone treated by clove buds) ($P < 0.001$) too. There was not a significant difference between groups of III and IV ($P > 0.05$) (Figure 1).

Discussion

In this study we examined some morphologic variables of injury to the renal tubular cells including degeneration, flattening, necrosis, and dilatation to detect the nephroprotective feature of clove bud against CIN-AKI. This study showed a significant difference in various types of injury (degeneration, flattening, necrosis, and dilatation) among the groups, while we found a significant difference between groups II (contrast media group) and III (rats pretreated by clove buds) and also a significant difference between groups II (contrast media group) and IV (rats post-pone treated by clove buds). However, there was not a significant difference between pretreated or post-pone treated rats with clove bud's groups of III versus IV. The findings showed that post-pone treatment of clove was also effective to mitigate the injury induced by contrast media. Renal proximal tubular cells are exposed to various intracellular accumulation of drugs or toxicants. Renal toxicity by drugs is the primary trigger of renal insufficiency which may result in acute renal failure and chronic renal failure and, finally, end-stage kidney failure. This study firstly showed the renoprotective prosperity of clove buds against contrast nephropathy and secondly post-pone treatment efficacy as well as the pretreatment by this herbal drug. Previously in an animal model study, Abozid et al showed that rats treated with clove or clove essential oil strangely inhibited the elevation of plasma levels of AST, ALT, compared with hydrogen peroxide treated rats alone. They also detected a significant decrease in renal markers such as urea and creatinine in the group of hydrogen peroxide and clove compared with hydrogen peroxide treated alone. Plasma antioxidant state (malondialdehyde content and catalase activity), also showed the same ameliorative property against hydrogen peroxide toxicity. Abozid et al suggested that extract of clove or clove essential oil has hepatoprotective and renoprotective effects against hydrogen peroxide-induced oxidative stress on both liver and kidney (13). Similarly to examine the potency of Clove on malondialdehyde and superoxide dismutase in the liver of Rabbits under hypercholesterolemia situation, Mu'nisa et al found that clove leaf extract could overwhelm superoxide dismutase and malondialdehyde elevations in rabbits' liver tissue under situation of hypercholesterolemia. Accordingly, Clove kept superoxide dismutase activity (14). To find,

Table 2. Intergroup comparison of types of renal injuries

Comparison between groups	Mean ± SD			
	Degeneration	Dilatation	Necrosis	Flattening
Control	1.25 ± 1.70	0.00 ± 0.00	0.00 ± 0.00	0.00 ± 0.00
Contrast media	32.10 ± 12.81	26.00 ± 5.91	15.20 ± 7.16	3.96 ± 13.90
Clove + Contrast media	12.60 ± 3.47	4.50 ± 1.90	5.2 ± 2.20	3.30 ± 0.95
Contrast media + Clove	7.20 ± 2.97	4.90 ± 0.99	3.20 ± 0.79	0.70 ± 2.50
Total	13.34 ± 13.40	8.85 ± 10.65	5.90 ± 6.80	5.74 ± 4.93
F (ANOVA)	37.525	137.412	30.324	88.595
P value	0.001	0.001	0.001	0.001

Table 3. Comparison of the sum of morphological variables of injury (degeneration, flattening, necrosis and dilatation) between groups

Comparison between groups	Mean difference (I-J) ± SD	P value
Control vs. Contrast media	-85.50 ± 4.82	<0.001
Control vs. Clove + Contrast media	-23.90 ± 4.82	<0.001
Control vs. Contrast media + Clove	-16.10 ± 4.82	<0.012
Contrast media vs. Clove + Contrast media	61.60 ± 4.82	<0.001
Contrast media vs. Contrast media + Clove	69.40 ± 4.82	<0.001
III vs. IV	7.80 ± 4.82	0.680

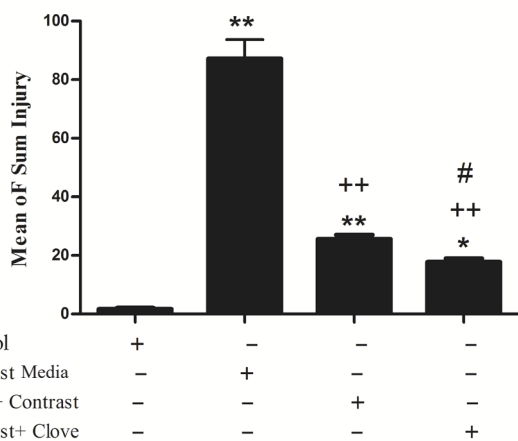


Figure 1. Bars show means ± SD (n=10/group) of the sum of the morphologic variables of injury in each group. *P < 0.05, **P < 0.001, significantly different from control group; +P < 0.05, ++P < 0.001, significantly different from contrast media group; #P < 0.05, ##P < 0.001, significantly different from clove + contrast media group.

the efficacy of *S. aromaticum* essential oil against kidney intoxication by lead in rats during development, Adli and Hachem delectated that the use of essential oil clove significantly reduced the previous lead-induced biochemical modifications in serum and kidney tissue

as well as the histological and cellular modifications. They concluded that the essential oil of *S. aromaticum* is efficient against lead nephrotoxicity (15). To find the protecting impact of *S. aromaticum* against ethotrexate-induced liver and kidney nephrotoxicity in rats, Al-Azem et al found that rats treated by methotrexate showed significant histopathological changes in renal tissues like degeneration, inflammatory cell infiltration, necrosis, and hemorrhage. While alteration of kidney tissues was less observed in rats treated with methotrexate and essential clove oil (16).

Conclusions

In conclusion, hydroalcoholic extract of clove buds (*S. aromaticum*) can effectively ameliorate CI-AKI in an animal study. Importantly, post-pone treatment of this herbal drug was as effective as pre-treatment.

Authors' contribution

PN and HN designed the research. EB conducted the animal study. AHD and SM supervised the study. PN, HN, NH, BY, MAS and MRKF prepared the final draft of the article. PN analyzed the data. HN studies the pathologies. All authors read and signed the final paper.

Conflicts of interest

As the corresponding author to this study, HN acts as the Editor-in-Chief of the journal. It is hereby declared that its collaboration with the journal has affected neither the peer-review process nor the acceptance of the study. Other authors declare that they have no competing interest.

Ethical considerations

Ethical issues (including plagiarism, misconduct, data fabrication, falsification, double publication or submission, redundancy) have been completely observed by the authors.

Funding/Support

This study was also approved and supported by Ethics

Committee of NIMAD (national institute for medical research development in Iran (#963554).

References

1. Gruberg L, Mintz GS, Mehran R, Gangas G, Lansky AJ, Kent KM, et al. The prognostic implications of further renal function deterioration within 48 h of interventional coronary procedures in patients with pre-existent chronic renal insufficiency. *J Am Coll Cardiol*. 2000; 36:1542-8. doi: 10.1016/S0735-1097(00)00917-7.
2. Berns AS. Nephrotoxicity of contrast media. *Kidney Int*. 1989;36:730-740.
3. Rudnick MR, Goldfarb S, Tumlin J. Contrast-induced nephropathy: is the picture any clearer? *Clin J Am Soc Nephrol*. 2008;3:261-2. doi: 10.2215/CJN.04951107.
4. Manda P, Srinivasa Rao PVLN, Bitla AR, Vinapamula KS, Jeyaseelan L, Rajasekhar D, et al. Study of contrast-induced oxidative stress in nondiabetic patients undergoing coronary angiography. *Saudi J Kidney Dis Transpl*. 2019;30:45-52.
5. Tumlin J, Stacul F, Adam A, Becker CR, Davidson C, Lameire N, et al. Pathophysiology of contrast-induced nephropathy. *Am J Cardiol*. 2006;98:14K-20K. doi: 10.1016/j.amjcard.2006.01.020.
6. Andreucci M, Solomon R, Tasanarong A. Side effects of radiographic contrast media: pathogenesis, risk factors, and prevention. *Biomed Res Int*. 2014; 2014:741018. doi: 10.1155/2014/741018.
7. Mueller C, Buerkle G, Buettner HJ, Petersen J, Perruchoud AP, Eriksson U, et al. Prevention of contrast media-associated nephropathy: randomized comparison of 2 hydration regimens in 1620 patients undergoing coronary angioplasty. *Arch Intern Med*. 2002;162:329-36. doi: 10.1001/archinte.162.3.329.
8. Dennis JM, Witting PK. Protective Role for Antioxidants in Acute Kidney Disease. *Nutrients*. 2017;9(7):E718. doi: 10.3390/nu9070718.
9. Kelly AM, Dwamena B, Cronin P, Bernstein SJ, Carlos RC. Meta-analysis: Effectiveness of drugs for preventing contrast-induced nephropathy. *Ann Intern Med*. 2008;148:284-94.
10. Elkomy A, Aboubakr M, Ibrahim S, Abdelhamid Y. Protective effects of *Syzygium aromaticum* oil (Clove) against acrylamide induced hepatic, renal, and testicular toxicity in rats. *Int J Pharmacol Toxicol*. 2018;6(1):12-17.
11. Cortés-Rojas DF, de Souza CR, Oliveira WP. Clove (*Syzygium aromaticum*): a precious spice. *Asian Pac J Trop Biomed*. 2014;4:90-6. doi: 10.1016/S2221-1691(14)60215-X.
12. Akila G, Djamil K, Nawal D, Saadia B. Comparative study of antihypertensive and antioxidant effects of clove and metformin on renal dysfunction in streptozotocin-induced diabetic rats. *Pharm Nutr*. 2018;6(1):37-44.
13. Abozid MM, EL-Sayed SM. Antioxidant and protective effect of clove extracts and clove essential oil on hydrogen peroxide treated rats. *Int J Chem Tech Res*. 2013;5(4):1477.
14. Mu'nisa A, Manalu W, Wresdiyati T, et al. The Effect of clove leaf methanol extract on the profiles of superoxide dismutase and malondialdehyde in the liver of rabbits under hypercholesterolemia condition. *Transl Biomed*. 2015;6:2.
15. Adli DEH, Hachem K. The efficiency of *Syzygium aromaticum* essential oil against renal intoxication by lead in rats during development. *Biosci Res*. 2018;15(3):2126-2133.
16. Abd Al-azem D, Karim H, Al-Derawi, Sahar A.A. Malik Al-Saadi. The protective effects of *Syzygium aromaticum* essential oil extract against methotrexate induced hepatic and renal toxicity in rats. *J Pure Appl Microbiol*. 2019;13:505-15.

Copyright © 2020 The Author(s); Published by Society of Diabetic Nephropathy Prevention. This is an open-access article distributed under the terms of the Creative Commons Attribution License (<http://creativecommons.org/licenses/by/4.0>), which permits unrestricted use, distribution, and reproduction in any medium, provided the original work is properly cited.