

Journal of Nephrologist



Effect of sodium hydrogen sulfide (NaHS) on contrast-induced acute kidney injury; an experimental histopathological study

Parto Nasri¹, Pegah Noorshargh², Niloufar Hooshyar³, Mahsa Akafzadeh Savari⁴, Banafsheh Yalameha⁵, Elnaz Golestaneh⁶, Mohammadreza Khosravifarsani⁷, Saied Mardani⁸, Ali Hasanpour Dehkordi⁹, Azar Baradaran^{4,10,11*}, Elham Bijad¹², Behzad Ghasemi¹³, Nafiseh Nowrouzi¹³

¹Infectious Diseases and Tropical Medicine Research Center, Isfahan University of Medical Sciences, Isfahan, Iran

²Alzahra Research Institute, Isfahan University of Medical Sciences, Isfahan, Iran

³Faculty of Medicine, Isfahan University of Medical Sciences, Isfahan, Iran

⁴Nickan Research Institute, Isfahan, Iran

⁵Department of Biochemistry, Faculty of Medicine, Lorestan University of Medical Sciences, Khorramabad, Iran

⁶Faculty of Pharmacy, Isfahan University of Medical Sciences, Isfahan, Iran

⁷Cancer Prevention Research Center, Isfahan University of Medical Sciences, Isfahan, Iran

⁸Department of Internal Medicine, Medicine Faculty, Shahrekord University of Medical Sciences, Shahrekord, Iran

⁹Social Determinants of Health Research Center, Shahrekord University of Medical Sciences, Shahrekord, Iran

¹⁰Inflammation and Tissue Response Research Center, Isfahan, Iran

¹¹Department of Pathology, Isfahan, University of Medical Sciences, Shahrekord, Iran

¹²Medical Plants Research Center, Basic Health Sciences Institute, Shahrekord University of Medical Sciences, Shahrekord, Iran

¹³Faculty of Pharmacy, Pécs University, Pécs, Hungary

ARTICLE INFO

Article type:
Original Article

Article history:
Received: 10 May 2019
Accepted: 4 September 2019
Published online: 20 October 2019

Keywords:
Acute kidney injury
Iodinated contrast media
Sodium hydrogen sulfide
Reactive oxygen species

ABSTRACT

Introduction: Contrast-induced nephropathy (CIN) is associated with a minimum increase of 25% of the creatinine base or an increase in creatinine of 0.5 mg/dL during 2-3 days after the administration of the contrast agent

Objectives: The present investigation was designed to examine the effect of sodium hydrogen sulfide (NaHS) on contrast-induced acute kidney injury in rats.

Materials and Methods: Forty male Wistar rats randomly assigned into four groups, 10 rats for each group. Group 1; normal rats (control group; sham group); they did not receive any drugs. Group 2; rats were received 10 mL/kg as a single dose of iodixanol (contrast media) by intravenous (IV) injection. Group 3; they received 10 mg/kg of NaHS by intraperitoneal (IP) injection for three days, while in day forth, rats received a single dose of iodixanol (10 mL/kg). Group 4; rats of this group, first received a single dose of iodixanol (10 mL/kg). Then rats were treated by NaHS (10 mg/kg) by intraperitoneal (IP) injection for 3 days (days 2, 3 and 4). The kidneys were removed immediately after sacrificing and prepared for morphological examination. Kidney sections were examined for intensity of kidney damage by examination for degeneration, flattening, and necrosis of renal tubular cells and also dilatation of tubular lumen.

Results: We detected a significant difference between groups regarding the morphologic variables of damage ($P=0.001$; one-way ANOVA). A significant difference of morphologic variables of damage (degeneration, flattening, necrosis, and dilatation) among the groups was seen too ($P=0.001$; one-way ANOVA). The study showed a significant difference between groups II (contrast media) with III (rats pretreated by NaHS) ($P<0.001$). Moreover, we detected a significant difference between groups II (contrast media) and IV (rats post-pone treated by NaHS) ($P<0.001$). However, there was not a significant difference between the groups of III and IV ($P>0.05$).

Conclusion: Post-pone treatment of NaHS was as effective as the pretreatment to mitigate the renal damage induced by contrast media.

Implication for health policy/practice/research/medical education:

In an experimental study we found that post-pone treatment of sodium hydrogen sulfide was also effective to mitigate the renal damage induced by contrast media.

Please cite this paper as: Nasri P, Noorshargh P, Hooshyar N, Akafzadeh Savari M, Yalameha B, Golestaneh E, et al. Effect of sodium hydrogen sulfide (NaHS) on contrast-induced acute kidney injury; an experimental histopathological study. J Nephrologist. 2022;x(x):e9835. DOI: 10.15171/jnp.2022.9835.

*Corresponding author: Prof. Azar Baradaran, Email; azarbaradaran@med.mui.ac.ir

Introduction

Contrast-induced nephropathy (CIN) is associated with a minimum increase of 25% of the creatinine base or an increase in creatinine of 0.5 mg/dL during 2-3 days after the administration of the contrast agent. CIN is the third cause of acute renal failure and hospital stay. The incidence of CIN in normal people is less than 3%, while it can reach up to 50% in high-risk patients, such as diabetic patients or people with kidney failure (1). Generally, contrast media (CM) contributes to the occurrence of renal failures by three routes including hemodynamic effects, direct CM tubular cell toxicity, and endogenous biochemical disturbance. Injection of contrast agents induces the generation of oxygen free radicals, increases lipid peroxidation, and reduces antioxidant enzyme activity (2). Also, it has been displayed that CM leads to cell death and hypoxic damage by decreased blood flow. Thus, the application of compounds with antioxidant exclusivity can be an advantageous procedure in intercepting renal damage caused by CM (3).

Hydrogen sulfide (H₂S) is introduced as the third gasotransmitter after nitric oxide (NO) and carbon monoxide (CO). Three main enzymes contributing to endogenous synthesis pathways of this colorless gas are cystathionine β-synthase (CBS), cystathionine γ-lyase (CSE), and 3-mercaptopyruvate sulfurtransferase (3-MST) (4). H₂S possess significant functions in modulating vascular inflammation, endothelial function, proliferation, and apoptosis (5).

Furthermore, it can be pointed out to the other characteristic of H₂S such as its antioxidant effect that increases glutathione (GSH) production and the activity of the superoxide dismutase (SOD) enzyme to scavenge superoxide, also regulates mitochondria function by preventing ROS generation (6).

The findings have revealed that H₂S affected renal function and ameliorated multiple kidney disorders including nephrotoxicity, renal ischemia/reperfusion injury, and obstructive nephropathy (7). In addition, prescription of H₂S alleviates STZ-induced diabetic retinopathy through suppressing inflammation and eliminating oxidative stress (8).

Despite the key roles of H₂S in the body system, it unable to be routinely utilized for clinical therapy because of its gaseous creation (9). Recently, inorganic sulfide salts as sodium hydrogen sulfide (NaHS) have attracted the attention of many researchers toward the treatment of various diseases (10). It is indicated that drug-like H₂S donors as NaHS are able to release H₂S at an uncontrolled condition which can be advantageous against diabetic retinopathy and nephropathy (11,12). Therefore, NaHS as a novel therapeutic agent may attenuate oxidative stress status in renal failure.

Objectives

The present investigation was designed to examine the effect of NaHS on contrast-induced acute kidney injury in rats.

Materials and Methods

Drug

NaHS was purchased from Sigma Company (USA). This substance is the product of the half-neutralization of H₂S with sodium hydroxide.

Animals and study design

Forty male Wistar rats (mean weight; 200-250 g) in the Medical Plants Research Center in Shahrekord University of Medical Sciences were investigated. All animals were housed in stable laboratory condition (21-25°C and light cycle; 12 h dark-12 h light). Rats randomly assigned into four groups, 10 rats for each;

1. Group 1; normal rats (control group; sham group); they did not receive any drugs.
2. Group 2; rats were received 10 mL/kg as a single dose of iodixanol (CM) by intravenous (IV) injection.
3. Group 3; rats received 10 mg/kg of NaHS by intraperitoneal (IP) injection for three days, while in day forth, they received a single dose of iodixanol (10 mL/kg).
4. Group 4; rats of this group first received a single dose of iodixanol (10 mL/kg). Then rats treated by NaHS (10 mg/kg) by intraperitoneal (IP) injection for 3 days (days 2, 3 and 4).

Histopathological study

The kidneys were removed immediately after sacrificing and fixing with 10% formalin for morphological examination. Then, 3 μm-thick sections of renal tissues were prepared and stained with hematoxylin and eosin (H&E) for pathological evaluation. Kidney sections were examined by a light microscope for intensity of kidney damage by examination for degeneration, flattening and necrosis of renal tubular cells and also dilatation of tubular lumen. The slides were examined by a nephropathologist who was blinded to the animal groups. The morphologic lesions were presented as the mean percent for each morphologic variable. The morphologic lesions were presented as the mean percent for each morphologic variable. For comparing the morphologic variables of degeneration, flattening, necrosis and dilatation between the groups, we used a sum of four morphologic variables as a total injury.

Ethical issues

This experimental protocol was performed according to the regulations of the Research Ethics Committee

of Iranian Ethical Guidelines for the use of animals in research. Additionally, all animal experiments were in accordance with protocols approved by the United States National Institutes of Health (NIH, 1978). This study was also approved and supported by Ethics Committee of NIMAD (<http://nimad.ac.ir/>) (national institute for medical research development in Iran (# 963556)).

Statistical analysis

All parameters were summarized with mean and standard deviation (SD). One-way analysis of variance (ANOVA) and post-hoc tests (Bonferroni test) were applied for comparison of mean values between groups. To data analysis Prism GraphPad version 8 software was used. Accordingly, *P* values of less than 0.05 were assumed to be significant (*P*<0.05).

Results

Table 1 shows mean± SD of the sum of the morphologic variables of injury (degeneration, flattening, necrosis, and dilatation) in each group.

As Table 1 shows, we detected a significant difference between groups regarding the morphologic variables of damage (*P*=0.001; one-way ANOVA).

Table 2 shows a significant difference in morphologic variables of damage (degeneration, flattening, necrosis, and dilatation) among the groups (*P*=0.001; one-way ANOVA).

Table 3 shows the difference between the groups of II, III and IV (*P*<0.001; Bonferroni test).

Table 1. Mean ± SD of the sum of injury (degeneration, flattening, necrosis, and dilatation) in each group

Groups	Sum of injury	
	Mean	SD
Control	1.7	1.25
Contrast media	87.20	20.67
NaHS + Contrast media	10.40	1.35
Contrast media + NaHS	13.20	5.47
Total	28.12	36.30
F (ANOVA) = 136.770, <i>P</i> value = 0.001		

Table 2. Intergroup comparison of types of renal injuries

Comparison between groups	Mean ± SD			
	Degeneration	Dilatation	Necrosis	Flattening
Control	1.70±1.25	0.00± 0.00	0.00± 0.00	0.00± 0.00
Contrast media	32.10± 12.81	26.00±5.91	15.20±7.16	13.90±3.96
NaHS + Contrast media	2.60 ±0.84	3.00± 0.67	2.80± 1.23	2.00± 0.67
Contrast media + NaHS	7.00 ±3.06	3.80±1.23	0.70±1.49	1.70±0.67
Total	10.85±14.11	8.20± 10.90	4.67± 7.19	4.40± 5.94
F (ANOVA)	46.849	155.783	36.813	98.787
<i>P</i> value	0.001	0.001	0.001	0.001

We found a significant difference between groups II (CM) with III (rats pretreated by NaHS) (*P*<0.001). Moreover, we detected a significant difference between groups II (CM) and IV (rats post-pone treated by NaHS) (*P*<0.001). However, there was not a significant difference between the groups of III and IV (*P*>0.05) (Figure 1).

Discussion

Acute kidney injury (AKI) is one of the important complications of the use of contrast agents in imaging and interventional techniques. Considering to the recent investigations that indicated the hydrogen sulfide (H₂S) plays an important role in the improvement of renal disorders such as AKI (13), the present study was designed to examine the NaHS effect as an H₂S donor on contrast-induced acute kidney injury (CI-AKI) in the animal model.

The findings of the present study revealed a remarkable difference in various types of renal injuries including degeneration, flattening, necrosis, and dilatation between all of the groups. In addition, the significant differences were observed between groups II (CM group) and III (rats pretreated by NaHS) and between groups II (CM group) and IV (rats post-pone treated by NaHS). However, there was no significant difference between pretreated or post-pone treated rats with NaHS groups of III versus IV.

In fact, morphological and functional alterations induced in the kidney tissue can be due to the accumulation and absorption of the medications and toxic compositions including contrast agents in tubule cells. Furthermore, in this study, the administration of NaHS had a nephroprotective effect against CI-AKI by post-pone treatment as well as the NaHS pretreatment. In agreement with our results, other studies documented the protective function of H₂S and H₂S donors in kidney damage such as nephrotoxicity and diabetic nephropathy. In a study, Qian et al reported that S-propargyl-cysteine as a novel hydrogen sulfide (H₂S)-releasing compound able to ameliorate renal function by reducing the levels of urine, creatinine, albuminuria and kidney weight/body weight. Also, their results demonstrated that S-propargyl-cysteine

Table 3. Comparison of the sum of morphological variables of injury (degeneration, flattening, necrosis, and dilatation) between groups

Comparison between groups	Mean difference (I-J) ± SD	P value
Control vs. Contrast media	-85.50±4.80	<0.001
Control vs. NaHS + Contrast media	-8.70±4.80	<0.001
Control vs. Contrast media + NaHS	-11.50±4.80	<0.012
Contrast media vs. NaHS + Contrast media	76.80±4.80	<0.001
Contrast media vs. Contrast media + NaHS	74.00±4.80	<0.001
NaHS + Contrast media vs. Contrast media + NaHS	-2.80±4.80	0.680

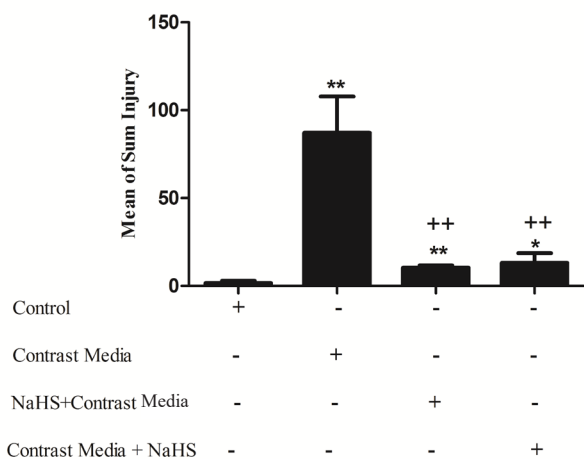


Figure 1. Bars show means ± SD (n=10/group) of the sum of the morphologic variables of injury in each group.

*P < 0.05, **P < 0.001, significantly different from control group. *P < 0.05, **P < 0.001, significantly different from CM group. #P < 0.05, ##P < 0.001, significantly different from NaHS+ CM group.

possesses an effective role in histological evaluations in STZ-induced diabetic nephropathy (9).

In another study, it was displayed that NaHS amends renal failure due to cisplatin in rats and the admiration of NaHS mitigated histological damages, 24-hour urine protein excretion, serum urea and creatinine (14).

To assess the efficacy of H2S in protecting kidney against ischemia-reperfusion injury, Hunter et al., offered that H2S therapy improved kidney injury by reducing the levels of urea, creatinine, and TNF-α. Furthermore, they conveyed that H2S can attenuate the severity of renal neutrophil infiltration (15).

It seems that the renoprotective effect of NaHS on the kidney damage and dysfunction be because of its exclusive

properties like anti-apoptotic, anti-inflammatory, and anti-oxidative and also the interference of NaHS in the various processes such as inflammation, apoptosis, ROS production, DNA synthesis, and matrix proteins synthesis (4,16,17).

Conclusion

In conclusion, NaHS can effectively ameliorate contrast-induced acute kidney injury in an animal study. Importantly, post-pone treatment of NaHS was as effective as pre-treatment.

Authors' contribution

PN and AB designed the research. EB conducted the animal study. AHD and SM supervised the study. PN, HN, NH, BY, EG, MAS and MRKF prepared the final draft of the article. PN analyzed the data. AB studies the pathologies. All authors read and signed the final paper.

Conflicts of interest

The authors declare that they have no competing interests.

Ethical considerations

Ethical issues (including plagiarism, misconduct, data fabrication, falsification, double publication or submission, redundancy) have been completely observed by the authors.

Funding/Support

This study was also approved and supported by NIMAD (<http://nimad.ac.ir/>) (national institute for medical research development in Iran (#963556)).

References

- Bartorelli AL, Marenzi G. Contrast induced nephropathy. *J Intervent Cardiol.* 2008; 21(1):74-85. doi: 10.1111/j.1540-8183.2007.00318.x.
- Katzberg RW. Contrast medium-induced nephrotoxicity: which pathway? *Radiology.* 2005;235(3):752-5.
- Ari E, Kedrah AE, Alahdab Y, Bulut G, Eren Z, Baytekin O, et al. Antioxidant and renoprotective effects of paricalcitol on experimental contrast-induced nephropathy model. *Br J Radiol.* 2012;85(1016):1038-43. doi: 10.1259/bjr/16327485.
- Cao X, Bian JS. The Role of Hydrogen Sulfide in Renal System. *Front Pharmacol.* 2016;7:385.
- Whiteman M, Le Trionnaire S, Chopra M, Fox B, Whatmore J. Emerging role of hydrogen sulfide in health and disease: critical appraisal of biomarkers and pharmacological tools. *Clin Sci (Lond).* 2011;121(11):459-88.
- Kolluru GK, Shen X, Bir SC, Kevil CG. Hydrogen sulfide chemical biology: pathophysiological roles and detection. *Nitric Oxide.* 2013; 35:5-20. doi: 10.1016/j.niox.2013.07.002
- Mansouri E. Effects of sodium hydrogen sulfide (a H2S

- donor) on acute kidney injury. *J Nephropathol*. 2018;7(1):1-3.
8. Si YF, Wang J, Guan J, Zhou L, Sheng Y, Zhao J. Treatment with hydrogen sulfide alleviates streptozotocin-induced diabetic retinopathy in rats. *Br J Pharmacol*. 2013;169(3):619–631. doi: 10.1111/bph.12163.
 9. Qian X, Li X, Ma F, Luo S, Ge R, Zhu Y. Novel hydrogen sulfide-releasing compound, S-propargyl-cysteine, prevents STZ-induced diabetic nephropathy. *Biochem Biophys Res Commun*. 2016;473(4):931-938. doi: 10.1016/j.bbrc.2016.03.154.
 10. Zhao Y, Biggs TD, Xian M. Hydrogen sulfide (H₂S) releasing agents: chemistry and biological applications. *Chem Commun (Camb)*. 2014;50(80):11788-805.
 11. Si YF, Wang J, Guan J, Zhou L, Sheng Y, Zhao J. Treatment with hydrogensulfide alleviates streptozotocin-induced diabetic retinopathy in rats. *Br J Pharmacol*. 2013;169(3):619–631.
 12. Safar MM, Abdelsalam RM. H₂S donors attenuate diabetic nephropathy in rats: Modulation of oxidant status and polyol pathway. *Pharmacol Rep*. 2015;67(1):17-23.
 13. Feliens D, Lee HJ, Kasinath BS. Hydrogen Sulfide in Renal Physiology and Disease. *Antioxid Redox Signal*. 2016;25(13):720-731. doi: 10.1089/ars.2015.6596.
 14. Cao X, Zhang W, Moore PK, Bian J. Protective smell of hydrogen sulfide and polysulfide in cisplatin-induced nephrotoxicity. *Int J Mol Sci*. 2019;20(2):313. doi: 10.3390/ijms20020313.
 15. Hunter JP, Hosgood SA, Patel M, Rose R, Read K, Nicholson ML. Effects of hydrogen sulphide in an experimental model of renal ischaemia–reperfusion injury. *Br J Surg*. 2012;99(12):1665-71. doi: 10.1002/bjs.8956.
 16. Kasinath BS. Hydrogen sulfide to the rescue in obstructive kidney injury. *Kidney Int*. 2014;85(6):1255-8. doi: 10.1038/ki.2013.529.
 17. Xia M, Chen L, Muh RW, Li P-L, Li N. Production and actions of hydrogen sulfide, a novel gaseous bioactive substance, in the kidneys. *J Pharmacol Exp Ther*. 2009; 329:1056–1062.

Copyright © 2020 The Author(s); Published by Society of Diabetic Nephropathy Prevention. This is an open-access article distributed under the terms of the Creative Commons Attribution License (<http://creativecommons.org/licenses/by/4.0>), which permits unrestricted use, distribution, and reproduction in any medium, provided the original work is properly cited.