

# Journal of Nephropathology



## Tenofovir induced acute kidney injury and its outcome; an Indian perspective

Sreedhara C. Gurusiddaiah<sup>1</sup>, Bhushan C Shetty<sup>2</sup>, Kishan Aralapuram<sup>1\*</sup>, Shashank Shetty<sup>1</sup>, Mythri Shankar<sup>1</sup>, Mahesha Vankalakunti<sup>3</sup>

<sup>1</sup>Department of Nephrology, Institute of Nephro-Urology, Bangalore, India

<sup>2</sup>Department of Nephrology, Kasturba Medical College Mangalore, Manipal Academy of Higher Education, Manipal, India

<sup>3</sup>Department of Laboratory Medicine, Manipal Hospitals, Bangalore, India

### ARTICLE INFO

*Article type:*  
Original Article

*Article history:*  
Received: 19 November 2021  
Accepted: 27 February 2023  
Published online: 18 March 2023

*Keywords:*  
Tenofovir  
Acute kidney injury  
Proximal tubules  
Renal pathology  
Human immunodeficiency virus

### ABSTRACT

**Introduction:** Tenofovir remains the cornerstone drug in various antiretroviral regimens and is commonly associated with renal failure in susceptible individuals with a renal biopsy suggestive of proximal tubular injury.

**Objectives:** To investigate clinical, histopathological and outcome findings in tenofovir-induced nephrotoxicity patients.

**Patients and Methods:** Between August 1, 2014, and March 31, 2017, an observational study was conducted in a government-run tertiary care facility in South India. All patients receiving a regimen based on tenofovir disoproxil fumarate (TDF) and testing positive for human immunodeficiency virus (HIV) were included. A renal biopsy was performed when needed.

**Results:** A total of 27 cases were identified, with a mean age of  $45.03 \pm 12.95$  years, while 19 (70%) of them were men. Mean creatinine and mean proteinuria among the participants were  $5.78 \pm 2.71$  mg/dL and  $1643.96 \pm 1056.44$  mg/dL, respectively, at the time of the renal biopsy. Interval between TDF treatments to kidney biopsies ranged between 7 to 52 weeks with mean ( $\pm$ SD) of  $30.8 \pm 22$  weeks. Phosphaturia and glycosuria were found in 10 (37.03%) and 8 (29.5%) patients respectively, all of whom had normoglycemia. In contrast to the remaining 13 instances, which all had moderate to severe diffuse inflammation, 14 patients exhibited toxic proximal tubular damage along with mild and localized interstitial inflammation. Hemodialysis was required by 10 individuals. A total of 22 patients were monitored after TDF was stopped, while 17 (77.27%) of them had fully recovered renal function at the end of monitoring period.

**Conclusion:** This study demonstrates that TDF nephrotoxicity is a reversible form of toxic acute tubular necrosis with concurrent interstitial inflammation that affects the proximal tubules. As a result, it is crucial to carefully monitor renal parameters in these patients.

### *Implication for health policy/practice/research/medical education:*

When used by vulnerable people, the first-line antiviral drug tenofovir frequently causes nephrotoxicity. This study was conducted to examine demographic data, clinical manifestations of tenofovir nephrotoxicity, the histology of kidney biopsy specimens, and outcomes six months after drug discontinuation.

**Please cite this paper as:** Gurusiddaiah S, C Shetty B, Aralapuram K, Shetty S, Shankar M, Vankalakunti M. Tenofovir induced acute kidney injury and its outcome; an Indian perspective. J Nephropathol. 2023;12(3):e17306. DOI: 10.34172/jnp.2023.17306.

### Introduction

Kidneys are one of several organs that the human immunodeficiency virus (HIV) can impact in the body. Various renal syndromes can manifest with the progression of the illness. These may be chronic, subacute, or acute. Acute kidney injury (AKI) is reported in up to 10% of HIV-infected patients attending outpatient clinics (1). Pre-existing hypertension, tenofovir disoproxil fumarate

(TDF) toxicity, advanced HIV infection, co-infection with hepatitis C virus (HCV) and sepsis are the risk factors for AKI in HIV. AKI can lead to prolonged hospitalisation and associated mortality in HIV-infected patients (2,3).

Tenofovir disoproxil fumarate is the acyclic nucleoside reverse transcription inhibitor tenofovir diphosphate's prodrug. It prevents mitochondrial gamma DNA polymerase and RNA-dependent DNA polymerase from

\*Corresponding author: Kishan Aralapuram,  
Email: drkishan81@gmail.com, inunephroresidents@gmail.com

synthesising DNA. It is a cornerstone medicine in the antiretroviral therapy (ART) regimen due to its antiviral potency, easy administration and generally benign side effect profile.

### Objectives

1. To study the renal histopathological changes secondary to TDF
2. To study the associated risk factors, clinical features, and outcome.

### Patients and Methods

#### Study design

It is a prospective observational study of patients started on TDF-based ART who presented to our institute with renal dysfunction from August 1, 2014, to March 31, 2017. Patients were evaluated at baseline and the data collected from them includes; age, gender, risk factors for HIV infection, interval between tenofovir administration and occurrence of renal failure, past and current infections, creatinine, urine analysis, 24-hour urine protein, hemogram, serum electrolytes, peripheral blood CD4 count. The modified diet for renal disease (MDRD) formula was conducted to calculate creatinine clearance. When necessary, renal biopsies were carried out using a biopsy gun (BARD 16 or 18 G, 22 mm cutting edge) under ultrasound guidance. Microscopy using light and immunofluorescence was conducted on the biopsy cores. A single nephropathologist with knowledge of the patient's clinical history and HIV status analyzed the renal biopsy samples. Support for hemodialysis was

given as needed. There were 27 incidences of renal tubular damage associated with TDF administration. Outcomes were analyzed by measuring serum creatinine of study population at the end of six months.

Diagnostic criteria for tenofovir nephrotoxicity included an acute reduction in renal function, histological evidence of acute and/or chronic tubular injury, usage of TDF at the time of renal dysfunction and the lack of alternative causes of acute renal failure.

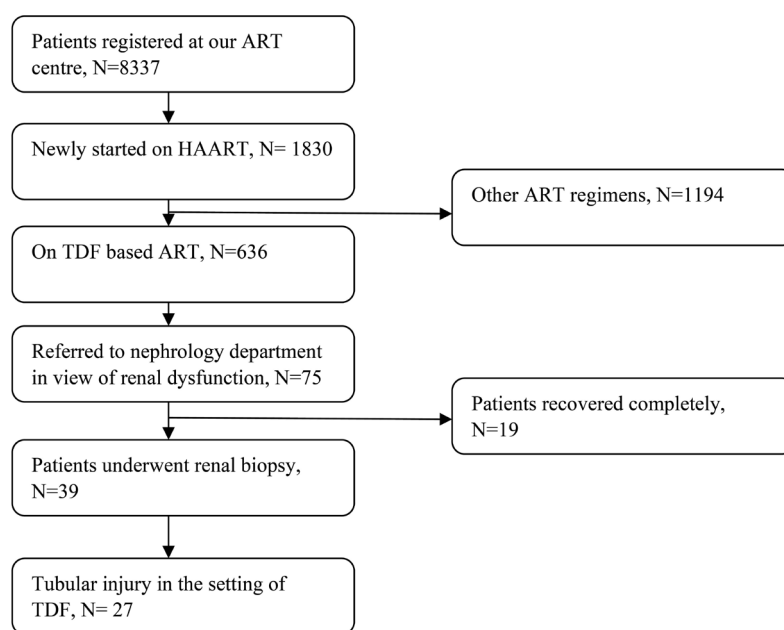
#### Statistical analysis

Descriptive statistics were conducted for analysis. For continuous variable mean was calculated along with standard deviation. For categorical variables frequencies, percentages and ratios were calculated.

### Results

During the study period, 8337 patients were registered at our ART center, of whom 1830 had just begun highly active antiretroviral therapy (HAART). Among them, 636 were on a tenofovir-based regimen. Seventy-five patients were referred to the institute during the study period for evaluation of renal dysfunction. Our institution serves the entire state of Karnataka as well as the bordering states of Andhra Pradesh and Tamil Nadu. Out of 75 patients, 19 recovered on their own; thus, they were not further examined. Further, 39 cases of unexplained renal failure or proteinuria were exposed to renal biopsies after chronic lesions were ruled out, and 27 of them had tubular injury associated with TDF use (Figure 1).

They were all using TDF together with lamivudine,



**Figure 1.** Flow chart showing the participants in our study. HAART, highly active antiretroviral therapy; TDF, tenofovir disoproxil fumarate; ART, antiretroviral therapy.

nevirapine, and efavirenz. In the cohort of 27 patients, 19 (70%) were men and 8 (30%) were women. The average age at biopsy was  $45.03 \pm 12.95$  years. Hepatitis B was also present in one case. Three of them had already undergone tuberculosis treatment. Among 23 patients, 19 of them with available viral levels had undetectable viral loads. The average CD4 count was  $412.81 \pm 167.98/\text{mL}$ .

Interval between TDF treatment to kidney biopsies was wide varied which ranged between 7 to 52 weeks with mean( $\pm$ SD) of  $30.8 \pm 22$  weeks. Renal biopsy indications included unexplained renal failure in seventeen patients and sub nephrotic proteinuria with milder renal dysfunction in ten. Proteinuria could be measured in 25 of the patients using a 24-hour collection.

The mean proteinuria among patients with timed 24-hour urine protein collection was  $1643.96 \pm 1056.44$  mg/dL. The average creatinine level was  $5.78 \pm 2.71$  mg/dL. Glycosuria was detected in ten patients (all had normal blood sugar levels) and phosphaturia in eight of them. Hemodialysis was required in 10 (37.03%) of the 27 patients.

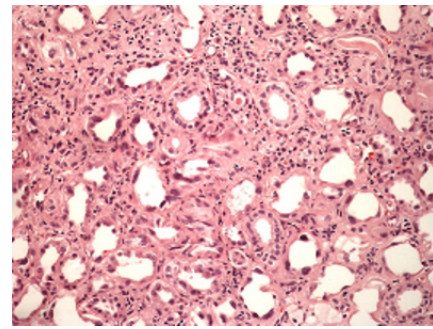
A total of 22 subjects were regularly followed for a period of six months. In 17 subjects, there was complete recovery in the form of normalization of serum creatinine. At the end of six months, two patients required hemodialysis.

Renal biopsy findings were suggestive of proximal tubular injury in all the biopsied patients, with a variable degree of interstitial inflammation (Figure 2). In some cases, lesions were classified as minor and confined, while the remaining 13 patients' lesions were described as moderate to severe and diffuse. Three of them had features of acute or chronic lesions with variable degrees of tubulointerstitial fibrosis and atrophy.

## Discussion

Various case series and reports have demonstrated the role of TDF in causing renal injury. Compared to previous case series where the mean peak creatinine ranged from 1.96, 3.9, and 5.7 mg/dL, our patients had a mean creatinine of  $5.78 \pm 2.71$  mg/dL (3-5), which reflects late referral to a specialist. Similar to earlier publications, our cohort had sub-nephrotic proteinuria and proximal tubular dysfunction, including normoglycemic glycosuria (37.03%) and phosphaturia (29.6%). In a study by Labarga et al (8), they observed 2% of people with non-diabetic glycosuria in TDF-treated patients with normal glomerular filtration rate; however, our study group showed a greater rate (37.03%), highlighting proximal tubular dysfunction as a contributing factor. Hence, a dipstick may be a cost-effective tool for detecting proximal tubular injury in TDF patients.

In an Italian study and data from post-marketing surveillance, TDF-induced AKI risk factors included



**Figure 2.** Significant acute tubular injury with nucleomegaly and hyperchromasia in the lining epithelium. Adjoining interstitium is edematous with lymphomononuclear infiltrates ( $\times 400$ ).

older age, a CD4 count with an odds ratio of 0.46 for each additional 50 CD4 cells/mL, male gender, co-infection with hepatitis C, the prescription of a concomitant nephrotoxic drug, and advanced HIV disease (6,7).

In contrast to the post-marketing safety data, which revealed a mean age of 42 years and a mean CD4 count of 215 cells/ml, our patient cohort had a greater male: female ratio of 2.3:1, a mean age of 45.03 (12.95), and a mean CD4 count of 412.81 (167.98) cells/ml. A mean of 30.8 weeks on tenofovir-based ART were spent by our patients. Twenty-three of the twenty-seven patients were older than 45 years, which highlights the importance of greater risk with advancing age. Most, if not all, were on proton pump inhibitors; whether they were contributory is unclear. Our patients showed improvement in renal function after TDF cessation; these outcomes are similar to the study done by Zimmermann et al (4).

Six of the 13 patients on TDF in a trial by Hermits et al achieved full recovery of renal function, while the other five patients displayed partial but considerable recovery (5).

In our study, of the 22 patients who were followed up, all but five had completely recovered renal function. Therefore, almost 22.72 percent of the population had developed chronic renal disease. Renal function decreases as a result of TDF administration, according to studies (9-11). After a year of treatment, it can drop to 13.3 mL/min/ $1.73 \text{ m}^2$  in those receiving TDF (9).

Human organic anion transporter (hOAT) allows the TDF to enter renal tubular epithelial cells at their basolateral pole, and from there it is released into the lumen by multidrug resistance protein (MRP) 2, MRP 4. The drug's intracellular concentration rises with increased plasma concentration or when apical secretion is stopped, which inhibits mitochondrial (MT) DNA polymerase, depletes mtDNA, and causes malfunction in the cell's oxidative respiratory chain. The proximal tubules exhibit these modifications.

Lack of ATP generation causes tiny molecules like

potassium, glucose, phosphate, uric acid, amino acids, and beta-2-microglobulin to no longer be absorbed by the tubular cells; these are then excreted in urine, which is defined as Fanconi syndrome (12-14). Our study provides a histopathological description of the light microscopy findings of TDF toxicity.

All of the patients in our biopsy series exhibited acute renal tubular injury, which ranged in severity from mild and localised in 14 cases to moderate to severe in 13. Three of them displayed signs of both chronic and acute interstitial nephritis. These light microscopy characteristics provide credence to the idea that TDF targets the proximal tubule's mitochondria in particular. Consequently, proximal tubular damage was prevalent. Ten of our patients had features suggestive of partial Fanconi syndrome; however, not all patients could be evaluated for Fanconi syndrome.

The Infectious Diseases Society of America (IDSA) advises measuring blood pressure and serum creatinine and checking all newly diagnosed HIV patients for proteinuria using a dipstick to find early tubular dysfunction.

Furthermore, in all patients receiving TDF medication whose estimated glomerular filtration rate was lower than 90 mL/min/1.72 m<sup>2</sup> at the time of TDF introduction, serum creatinine, serum phosphate, proteinuria, and glycosuria are also tested twice yearly. When prescribing other concurrent nephrotoxic medications or a protease inhibitor that has been increased by ritonavir (15), patients with hypertension and diabetes should be given special consideration.

The treatment of TDF-induced acute kidney injury is currently unknown. Most, if not all, of our patients responded positively to the drug's discontinuation, demonstrating AKI's reversibility. Reduction of nephrotoxicity by administration of drugs that regulate intracellular transport is an exciting option. In this regard, the HOAT-1 inhibitor probenecid was specifically noted as an inhibitor of the transport of TDF into the cells demonstrated by Izzedine et al (16).

Tenofovir-induced toxicity in rats AKI has identified the peroxisome proliferator-activated receptor-gamma agonist Rosiglitazone being protective (17). Although it prevents rats from developing proximal tubular dysfunction and renal failure brought on by tenofovir, the medicine has been discontinued due to cardiovascular safety concerns. These drugs may help in preventing or treating TDF-induced nephrotoxicity and need to be explored further.

At present, our government-run ART centre prescribes tenofovir as the first-line therapy in all new cases of HIV. The above clinicopathological findings and recommendations from the IDSA provide a guide for the prescription and close monitoring of these patients.

## Conclusion

This study, consisting of 27 patients with tenofovir-induced tubular injury, shows that though acute kidney injury is largely reversible after drug discontinuation in most of the cases however significant proportion had CKD at the end of six months. Identification of at-risk patients, values of serum creatinine, in addition to a urine dipstick for glycosuria, and close monitoring may provide an effective tool in a resource-limited country like ours to prevent TDF-induced AKI.

## Limitations of the study

This is a single centre study with small sample size. Follow up was done only for six months.

## Authors' contribution

Conceptualization: SCG, SS, BCS.

Methodology: KA.

Validation: SS.

Formal analysis: DSS.

Investigation: MV.

Resources: SS.

Data curation: SCG, BCS.

Writing—original draft: KA, SS.

Writing—review and editing: KA, BCS.

Visualization: MS.

Supervision: KA.

Project administration: SCG.

## Conflicts of interest

The authors declare that they have no competing interests.

## Ethical issues

The research followed the tenets of the Declaration of Helsinki. The Ethics Committee of Institute of Nephro-Urology, Bangalore approved this study. Accordingly, written informed consent was taken from all participants before any intervention. Besides, ethical issues (including plagiarism, data fabrication, double publication) have been completely observed by the authors.

## Funding/Support

None.

## References

1. Winston J, Deray G, Hawkins T, Szczech L, Wyatt C, Young B. Kidney disease in patients with HIV infection and AIDS. *Clin Infect Dis*. 2008;47:1449-57. doi: 10.1086/593099. PMID: 18947327.
2. Fernandez-Fernandez B, Montoya-Ferrer A, Sanz AB, Sanchez-Niño MD, Izquierdo MC, Poveda J, et al. Tenofovir nephrotoxicity: 2011 update. *AIDS Res Treat*. 2011;2011:354908. doi: 10.1155/2011/354908.

3. Rifkin BS, Perazella MA. Tenofovir-associated nephrotoxicity: Fanconi syndrome and renal failure. *Am J Med.* 2004;117:282-4. doi: 10.1016/j.amjmed.2004.03.025.
4. Zimmermann AE, Pizzoferrato T, Bedford J, Morris A, Hoffman R, Braden G. Tenofovir-associated acute and chronic kidney disease: a case of multiple drug interactions. *Clin Infect Dis.* 2006 Jan 15;42:283-90. doi: 10.1086/499048.
5. Herlitz LC, Mohan S, Stokes MB, Radhakrishnan J, D'Agati VD, Markowitz GS. Tenofovir nephrotoxicity: acute tubular necrosis with distinctive clinical, pathological, and mitochondrial abnormalities. *Kidney Int.* 2010;78:1171-7. doi: 10.1038/ki.2010.318.
6. Madeddu G, Bonfanti P, De Socio GV, Carradori S, Grosso C, Marconi P, et al; CISAI Group. Tenofovir renal safety in HIV-infected patients: results from the SCOLTA Project. *Biomed Pharmacother.* 2008;62:6-11. doi: 10.1016/j.biopha.2007.04.008.
7. Nelson MR, Katlama C, Montaner JS, Cooper DA, Gazzard B, Clotet B, et al. The safety of tenofovir disoproxil fumarate for the treatment of HIV infection in adults: the first 4 years. *AIDS.* 2007;21:1273-81. doi: 10.1097/QAD.0b013e3280b07b33.
8. Labarga P, Barreiro P, Martin-Carbonero L, Rodriguez-Novoa S, Solera C, Medrano J, et al. Kidney tubular abnormalities in the absence of impaired glomerular function in HIV patients treated with tenofovir. *AIDS.* 2009;23:689-96. doi: 10.1097/QAD.0b013e3283262a64.
9. Gallant JE, Parish MA, Keruly JC, Moore RD. Changes in renal function associated with tenofovir disoproxil fumarate treatment, compared with nucleoside reverse-transcriptase inhibitor treatment. *Clin Infect Dis.* 2005;40:1194-8. doi: 10.1086/428840.
10. Winston A, Amin J, Mallon P, Marriott D, Carr A, Cooper DA, et al. Minor changes in calculated creatinine clearance and anion-gap are associated with tenofovir disoproxil fumarate-containing highly active antiretroviral therapy. *HIV Med.* 2006;7:105-11. doi: 10.1111/j.1468-1293.2006.00349.x.
11. Mauss S, Berger F, Schmutz G. Antiretroviral therapy with tenofovir is associated with mild renal dysfunction. *AIDS.* 2005;19:93-5. doi: 10.1097/00002030-200501030-00012.
12. Rodriguez-Novoa S, Labarga P, Soriano V. Pharmacogenetics of tenofovir treatment. *Pharmacogenomics.* 2009;10:1675-85. doi: 10.2217/pgs.09.115.
13. Ray AS, Cihlar T, Robinson KL, Tong L, Vela JE, Fuller MD, et al. Mechanism of active renal tubular efflux of tenofovir. *Antimicrob Agents Chemother.* 2006;50:3297-304. doi: 10.1128/AAC.00251-06.
14. Kohler JJ, Hosseini SH, Green E, Abuin A, Ludaway T, Russ R, et al. Tenofovir renal proximal tubular toxicity is regulated by OAT1 and MRP4 transporters. *Lab Invest.* 2011;91:852-8. doi: 10.1038/labinvest.2011.48.
15. Gupta SK, Eustace JA, Winston JA, Boydston II, Ahuja TS, Rodriguez RA, et al. Guidelines for the management of chronic kidney disease in HIV-infected patients: recommendations of the HIV Medicine Association of the Infectious Diseases Society of America. *Clin Infect Dis.* 2005;40:1559-85. doi: 10.1086/430257.
16. Izzedine H, Harris M, Perazella MA. The nephrotoxic effects of HAART. *Nat Rev Nephrol.* 2009;5:563-73. doi: 10.1038/nneph.2009.142.
17. Libório AB, Andrade L, Pereira LV, Sanches TR, Shimizu MH, Seguro AC. Rosiglitazone reverses tenofovir-induced nephrotoxicity. *Kidney Int.* 2008;74:910-8. doi: 10.1038/ki.2008.252.

**Copyright** © 2023 The Author(s); Published by Society of Diabetic Nephropathy Prevention. This is an open-access article distributed under the terms of the Creative Commons Attribution License (<http://creativecommons.org/licenses/by/4.0>), which permits unrestricted use, distribution, and reproduction in any medium, provided the original work is properly cited.