

Journal of Nephrothology



Renal failure and pleural effusion; a diagnostic challenge

Sara Cardoso Fernandes^{1*}, Joana Marques¹, Mário Pinto², Mário Góis^{1,3}, Helena Sousa^{1,3},
Fernando Nolasco^{1,4}

¹Department of Nephrology, Hospital Curry Cabral, Centro Hospitalar Universitário de Lisboa Central, Lisboa, Portugal

²Department of Pulmonology, Hospital Santa Marta, Centro Hospitalar Universitário de Lisboa Central, Lisboa, Portugal

³Laboratory of Renal Morphology, Department of Nephrology, Hospital Curry Cabral, Centro Hospitalar Universitário de Lisboa Central, Lisboa, Portugal

⁴Nova Medical School, Faculdade de Ciências Médicas, Universidade Nova de Lisboa, Lisbon, Portugal

ARTICLE INFO

Article type:
Case Report

Article history:
Received: 12 November 2021
Accepted: 25 February 2023
Published online: 10 April 2023

Keywords:
Sjögren's syndrome
AA amyloidosis
Renal amyloidosis
Pleural amyloidosis

ABSTRACT

Sjögren's syndrome is a chronic inflammatory disorder mostly involving the exocrine glands. Extraglandular disease may occur in up to one quarter of patients. Kidney involvement is rare, more often manifested by tubular dysfunction secondary to tubulointerstitial nephritis. Primary glomerular disease is uncommon. The authors present the case of a 73-year-old woman with xerostomia and positivity for anti-Ro and anti-La antibodies admitted for acute kidney injury and exudative pleural effusion. Biopsy of salivary glands was compatible with Sjögren's syndrome. Extraglandular involvement was also confirmed by renal and pleural deposition of AA-amyloid. The patient was started on prednisolone followed by azathioprine with rapid improvement of lung disease. However, due to progressing renal disease and clinical deterioration, prognosis was guarded and the patient died. We describe a case of secondary amyloidosis with systemic involvement and infrequent clinical manifestations, briefly reviewing the key aspects of Sjögren's syndrome and AA-amyloidosis.

Implication for health policy/practice/research/medical education:

This clinical report describes a rare complication of Sjögren's syndrome presenting with multisystem involvement and rare manifestations. This case highlights the importance of making a prompt diagnosis of inflammatory conditions in order to avoid the development of AA amyloidosis, a serious illness that lacks effective therapeutic options.

Please cite this paper as: Fernandes SC, Marques J, Pinto M, Góis M, Sousa H, Nolasco F. Renal failure and pleural effusion; a diagnostic challenge. J Nephrothol. 2023;12(3):e17309. DOI: 10.34172/jnp.2023.17309.

Introduction

Sjögren's syndrome is a chronic, slowly progressive, inflammatory disorder of unknown origin (1,2). It may present alone (primary Sjögren's syndrome), or overlap with other rheumatic diseases such as rheumatoid arthritis, systemic lupus erythematosus or scleroderma (secondary Sjögren's syndrome) (1-3).

Sjögren's syndrome affects 0.01% to 0.1% of the general population (1,4,5). It predominantly occurs in middle-aged women, but individuals of all ages and genders can be affected (1,3-5).

The underlying mechanism of Sjögren's syndrome is not completely understood. Abnormal B and T-cell responses to auto-antigens (Sjögren's syndrome-related antigen A and Sjögren's syndrome-related antigen B, also known as anti-Ro/SSA and anti-La/SSB antibodies, respectively)

expressed by the epithelium of the affected organs leads to increased levels of cytokines and chemokines, lymphocytic infiltration and chronic inflammation of exocrine glands and also tissues (1).

Diagnostic criteria have been recently updated; individuals with at least one suggestive sicca symptom, who have a total score of at least 4 (based on weighted sum of five items), meet the criteria for Sjögren's syndrome (Table 1) (6).

Clinical presentation is extremely variable. Glandular Sjögren's syndrome is characterized by lymphocytic infiltration and destruction of the exocrine glands, mainly lacrimal and salivary glands, which results in keratoconjunctivitis sicca and/or xerostomia in more than 90% of affected patients (1,3). Extraglandular disease, once thought to be rare, occurs in up to 25% of patients

*Corresponding author: Sara Cardoso Fernandes,
Email: saracardfernandes@gmail.com, sara.fernandes@chlc.min-saude.pt

Table 1. Diagnostic criteria of Sjögren's syndrome

Diagnostic criteria	
For a positive diagnosis, the patient must meet:	
<ul style="list-style-type: none"> • Inclusion criteria* • None of the conditions listed as exclusion criteria** • Score ≥ 4 (when summing the weights from the following items) 	
Labial salivary gland with focal lymphocytic sialadenitis and focus score ≥ 1 foci/4 mm ²	3
Anti-SSA (Ro) +	3
Ocular staining score ≥ 5 (or van Bijsterveld score ≥ 4) on at least one eye	1
Schirmer ≤ 5 mm/5 min on at least one eye	1
Unstimulated whole saliva flow rate ≤ 0.1 mL/min	1

* Inclusion criteria: At least one symptom of ocular or oral dryness, defined as a positive response to at least one of the questions defined by ACR/EULAR.

** Exclusion criteria: History of head and neck radiation treatment; active hepatitis C infection (with positive polymerase chain reaction); acquired immunodeficiency syndrome; sarcoidosis; amyloidosis; graft-versus-host disease or IgG4-related disease.

and may affect multiple organ systems.

Kidney involvement is rare, affecting under 10% of patients (3,5). Two major pathophysiological processes are potentially involved; epithelial disease with a predominantly mononuclear lymphocytic infiltration resulting in tubulointerstitial nephritis (TIN) and non-epithelial disease with a secondary immune complex-mediated glomerulopathy (1,3,5). Acute or chronic TIN is the predominant lesion in biopsy-proven renal involvement of Sjögren's syndrome, found in about two thirds of patients (2-5,7). Renal tubular acidosis, more commonly distal rather than proximal, is the most common clinical finding (2-5,7). Primary glomerular disease, usually a cryoglobulinemic membranoproliferative pattern, is much rarer (3,5).

Case Presentation

The authors present the case of a 73-year-old female with a previous medical history of hypertension, iron-deficiency anemia and chronic musculoskeletal pain interpreted as fibromyalgia and treated with multiple analgesics.

During a previous hospitalization, she was diagnosed with chronic kidney disease and pleural effusion which prompted a thorough investigation. Diagnostic workup excluded infectious and neoplastic causes and, based on complaints of xerostomia and Raynaud's phenomenon, as well as positive antinuclear (ANA), anti-Ro and anti-La antibodies, a presumptive diagnosis of an autoimmune disease was made. She was discharged with serum creatinine 1.4 mg/dL, on hydroxychloroquine and referred to nephrology clinic for further investigation.

One month later, the patient was admitted to the nephrology department due to worsening renal function and relapsing pleural effusion. On admission, she presented with normocytic normochromic anemia (hemoglobin 10.7 g/dL), acute kidney injury KDIGO (kidney disease improving global outcomes) stage 1 (urea 61 mg/dL and serum creatinine 2.15 mg/dL); with urinalysis showing no evidence of proteinuria or other anomalies. Renal

ultrasound revealed normal sized kidneys with mildly increased echogenicity bilaterally and excluded obstructive disease. Kidney biopsy was conducted which showed A-amyloid deposits in the vasculature and interstitium, sparing glomeruli (Figures 1 and 2).

Meanwhile, a thoracentesis was performed, revealing an exudative pleural effusion with predominance of mononucleate cells (Figure 3). Bacteriological examinations were negative. Pleural biopsies were made and A-amyloid deposits were detected.

Given the complaints of xerostomia, Raynaud's

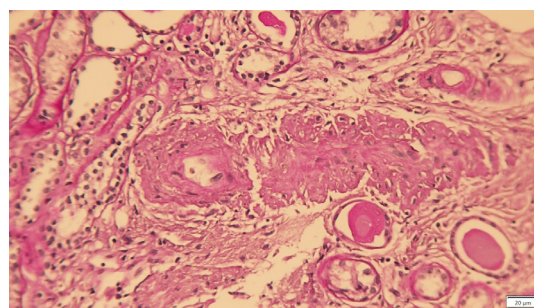


Figure 1. Periodic acid Schiff ($\times 160$) of kidney biopsy showing acellular, pale pink amorphous material deposition involving the arteries (mainly) and the interstitium. There is also tubular atrophy and intratubular casts.

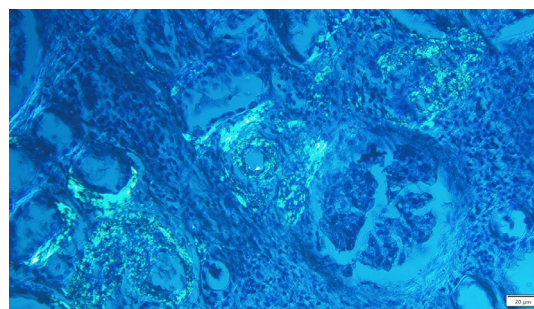


Figure 2. Polarized light ($\times 160$) of kidney biopsy demonstrating deposition of apple-green birefringent material around arteries and interstitium.

phenomenon and a positive Schirmer's test, the patient underwent salivary gland biopsy that revealed chronic grade III sialadenitis (Chisholm and Mason classification) and amyloid deposits (Figure 4). The diagnoses of Sjögren's syndrome (based the 2016 ACR/EULAR criteria) and amyloidosis of salivary glands were made.

A final diagnosis of systemic AA amyloidosis, with renal, pulmonary and salivary glandular involvement, was therefore established. Persistent hypotension refractory to midodrine prompted transthoracic echocardiography, with no signs of cardiac amyloidosis. After exclusion of other rheumatic diseases and neoplastic or infectious causes, it was assumed that the systemic amyloidosis was secondary to the Sjögren's syndrome.

The patient was started on prednisolone (60 mg/daily) aiming to control the underlying disease and later azathioprine was added as a steroid-sparing agent. Pleural effusion did not relapse. However, patients' renal function continued to worsen, reaching serum creatinine levels of 3.58 mg/dL (glomerular filtration rate 11 mL/min) in a severely malnourished patient, and she was started on dialysis. Clinical deterioration continued, through multiple infections, culminating in the death of the patient six months later.

Discussion

AA amyloidosis, also known as secondary amyloidosis, is a rare systemic disorder characterized by extracellular deposition of fibrils constituted by acute-phase reactant serum amyloid A protein (8). AA amyloidosis can be a consequence of any chronic inflammatory disease; however, rheumatoid arthritis is the most common cause, accounting for up to 40% of cases (9). Less frequent causes include other connective tissue disorders, chronic infections, inflammatory bowel disease, various malignancies and familial Mediterranean fever. Although rare, the association of Sjögren's syndrome and amyloidosis was first reported by Ooms et al, who described the case of a patient with long-standing primary Sjögren's syndrome presenting with acute renal failure and nephrotic syndrome caused by secondary renal amyloidosis (10). In the present case, the long-time complaints of xerostomia, xerophthalmia and musculoskeletal pain, as well as the exclusion of other diseases more often associated with AA amyloidosis, led to the assumption that the systemic amyloidosis was secondary to an undiagnosed and untreated Sjögren's syndrome.

The kidney is the organ more frequently involved in AA amyloidosis, accounting for approximately 90% of the cases (11,12). Renal involvement is usually characterized with glomerular amyloid deposition which can be manifested as asymptomatic proteinuria or overt nephrotic syndrome. However, in rare cases, amyloid deposition can

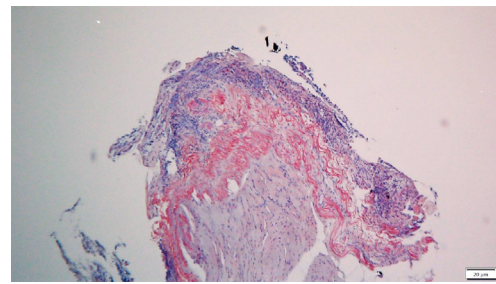


Figure 3. Congo red stain ($\times 63$) of a pleural biopsy showing sheets of Congo red positive amyloid material (apple-green birefringent under polarized light, not shown here).

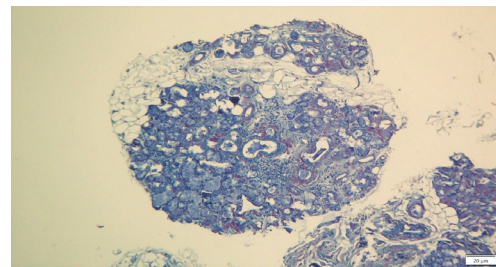


Figure 4. Congo red stain ($\times 63$) of a labial salivary gland biopsy demonstrating a periductal focus of lymphocytes and plasma cells consistent with focal lymphocytic sialadenitis. Note the concentric periductal deposition of Congo red positive amyloid material (apple-green birefringent under polarized light, not shown here).

occur solely in renal blood vessels and tubules, leading to slowly progressive chronic kidney disease without significant levels of proteinuria (13). Diagnosis is usually made by renal biopsy. Amyloid deposits can be identified with Congo Red staining, and have a typical apple-green birefringence on polarized light microscopy (14).

Other than renal involvement, the patient also had pulmonary amyloid deposits. Pulmonary amyloidosis is usually associated with AL amyloidosis and may present with diffuse parenchymal involvement, tracheobronchial infiltration, parenchymal nodules, pulmonary hypertension and, rarely, with pleural involvement (15). Pleural effusion occurs in 1 to 2% of patients with systemic amyloidosis and can be unilateral or bilateral; only one-third present as exudative effusions. Pleural effusions of amyloid origin are usually persistent, refractory to treatment and confer poor prognosis (16).

In the presented case, the authors also describe the coexistence of Sjögren's syndrome and amyloid deposits in the salivary gland biopsy, which, albeit rare, has also been reported (17).

AA amyloidosis is a serious condition associated with significant mortality when untreated.

Presently, there is no specific therapy for secondary amyloidosis; the preferred treatment aims to control the underlying inflammatory disease in order to suppress the production of serum amyloid A protein. Anticytokine

therapies, such as tumor necrosis factor (TNF) antagonists and the anti-interleukin-6 antagonist receptor tocilizumab, have shown some efficacy in patients with AA amyloidosis and underlying rheumatic disorders. Therapeutic management of Sjögren's syndrome is based on treatment of sicca syndrome symptoms, whereas immunosuppressive treatment should be reserved for severe systemic manifestations. Corticosteroids are recommended as first-line option at the minimum dose and length of time to control active disease; the addition of steroid-sparing agents may be necessary in patients with uncontrolled systemic disease, with no evidence supporting the choice of one agent over another (18,19). In this particular case, the patient was started on prednisolone 60 mg per day, and then azathioprine, an immunosuppressive agent recommended for the treatment of both renal and pulmonary manifestations of Sjögren's syndrome, was added.

Conclusion

This article describes a case of secondary amyloidosis with systemic involvement and infrequent clinical manifestations, reinforcing the importance of a prompt diagnosis and timely treatment of the underlying disease, in order to assure the best possible outcome.

Authors' contribution

Conceptualization: SCF, JM.

Methodology: SCF, JM.

Validation: FN.

Formal analysis: SCF, JM, MP.

Investigation: SCF, JM, MP.

Resources: HS, MG.

Data curation: FN.

Writing—original draft: SCF, JM.

Writing—review and editing: MP, FN.

Visualization: FN.

Supervision: FN.

Project administration: SCF.

Conflicts of interest

The authors declare that they have no competing interests.

Ethical issues

This case report was conducted in accord with the World Medical Association Declaration of Helsinki. The patient has given us a written informed consent for publication as a case report. Besides, ethical issues (including plagiarism, data fabrication, double publication) have been completely observed by the authors.

Funding/Support

None.

References

1. Brito-Zerón P, Baldini C, Bootsma H, Bowman SJ, Jonsson R, Mariette X, et al. Sjögren syndrome. *Nat Rev Dis Primers*. 2016;2:16047. doi: 10.1038/nrdp.2016.47.
2. Kronbichler A, Mayer G. Renal involvement in autoimmune connective tissue diseases. *BMC Med*. 2013;11:95. doi: 10.1186/1741-7015-11-95.
3. Evans R, Zdebek A, Ciurtin C, Walsh SB. Renal involvement in primary Sjögren's syndrome. *Rheumatology (Oxford)*. 2015;54:1541-8. doi: 10.1093/rheumatology/kev223.
4. Fogo AB, Lusco MA, Najafian B, Alpers CE. *AJKD Atlas of Renal Pathology: Kidney Disease in Primary Sjögren Syndrome*. *Am J Kidney Dis*. 2017;69:e29-e30. doi: 10.1053/j.ajkd.2017.04.003.
5. François H, Mariette X. Renal involvement in primary Sjögren syndrome. *Nat Rev Nephrol*. 2016;12:82-93. doi: 10.1038/nrneph.2015.174.
6. Shiboski CH, Shiboski SC, Seror R, Criswell LA, Labetoulle M, Lietman TM, et al; International Sjögren's Syndrome Criteria Working Group. 2016 American College of Rheumatology/European League Against Rheumatism classification criteria for primary Sjögren's syndrome: A consensus and data-driven methodology involving three international patient cohorts. *Ann Rheum Dis*. 2017;76:9-16. doi: 10.1136/annrheumdis-2016-210571.
7. Lin CY, Wu CH, Chen HA, Hsu CY, Wang LH, Su YJ. Long-term renal prognosis among patients with primary Sjögren's syndrome and renal involvement: A nationwide matched cohort study. *J Autoimmun*. 2020;113:102483. doi: 10.1016/j.jaut.2020.102483.
8. Papa R, Lachmann HJ. Secondary, AA, Amyloidosis. *Rheum Dis Clin North Am*. 2018;44(4):585-603. doi: 10.1016/j.rdc.2018.06.004.
9. Gertz MA, Kyle RA. Secondary systemic amyloidosis: response and survival in 64 patients. *Medicine (Baltimore)*. 1991;70:246-56.
10. Ooms V, Decupere M, Lerut E, Vanrenterghem Y, Kuypers DR. Secondary renal amyloidosis due to long-standing tubulointerstitial nephritis in a patient with Sjögren syndrome. *Am J Kidney Dis*. 2005;46:e75-80. doi: 10.1053/j.ajkd.2005.07.019.
11. Wechalekar AD, Gillmore JD, Hawkins PN. Systemic amyloidosis. *Lancet*. 2016 Jun 25;387:2641-54. doi: 10.1016/S0140-6736(15)01274-X.
12. Bunker D, Gorevic P. AA amyloidosis: Mount Sinai experience, 1997-2012. *Mt Sinai J Med*. 2012;79:749-56. doi: 10.1002/msj.21342.
13. Kurita N, Kotera N, Ishimoto Y, Tanaka M, Tanaka S, Toda N, et al. AA amyloid nephropathy with predominant vascular deposition in Crohn's disease. *Clin Nephrol*. 2013;79:229-32. doi: 10.5414/cn107151.
14. Kyle RA. Amyloidosis: a convoluted story. *Br J Haematol*. 2001;114:529-38. doi: 10.1046/j.1365-2141.2001.02999.x.
15. Milani P, Basset M, Russo F, Foli A, Palladini G, Merlini G. The lung in amyloidosis. *Eur Respir Rev*. 2017;26:170046. doi:10.1183/16000617.0046-2017.
16. Coolbear F, Bilawich AM, Tongson J, Adamo J, Churg

- A. Pleural amyloidosis imitating pleural malignancy. *Respir Med Case Rep.* 2017;20:195-197. doi: 10.1016/j.rmcr.2017.03.004.
17. Kweon SM, Koh JH, Lee HN, Kim E, So MW, Shin HJ, et al. Primary Sjogren syndrome diagnosed simultaneously with localized amyloidosis of the lacrimal gland: A case report. *Medicine (Baltimore).* 2018;97:e11014. doi: 10.1097/MD.00000000000011014.
18. Ramos-Casals M, Brito-Zerón P, Bombardieri S, Bootsma H, De Vita S, Dörner T, et al. EULAR-Sjögren Syndrome Task Force Group. EULAR recommendations for the management of Sjögren's syndrome with topical and systemic therapies. *Ann Rheum Dis.* 2020;79:3-18. doi: 10.1136/annrheumdis-2019-216114.
19. Saraux A, Pers JO, Devauchelle-Pensec V. Treatment of primary Sjögren syndrome. *Nat Rev Rheumatol.* 2016;12:456-71. doi: 10.1038/nrrheum.2016.100.

Copyright © 2023 The Author(s); Published by Society of Diabetic Nephropathy Prevention. This is an open-access article distributed under the terms of the Creative Commons Attribution License (<http://creativecommons.org/licenses/by/4.0>), which permits unrestricted use, distribution, and reproduction in any medium, provided the original work is properly cited.