

Journal of Nephrothology

CrossMark
click for updates

A renal transplant patient with COVID-19 presented with acute cellular rejection

Neda Soleimani^{ID}, Sahand Mohammadzadeh^{*ID}

Department of Pathology, Medical School, Shiraz University of Medical Sciences, Shiraz, Iran

ARTICLE INFO

Article type:
Case Report

Article history:
Received: 23 June 2022
Accepted: 14 July 2022
Published online: 20 July 2022

ABSTRACT

A 27-year-old man underwent a deceased kidney transplant. Three days after transplantation, COVID-19 was diagnosed for our patient. Immunosuppressants were reduced and a renal biopsy was conducted, which showed acute T cell-mediated rejection. We intended to share a case to help clinicians to understand the risks that kidney transplant recipients face.

Keywords: Kidney, Transplantation, Coronavirus

Implication for health policy/practice/research/medical education:

Our report of a COVID-19 infection in a renal transplant recipient with a successful outcome but differing clinical outcomes may act as a guidance for treating patients with this condition.

Please cite this paper as: Soleimani N, Mohammadzadeh S. A renal transplant patient with COVID-19 presented with acute cellular rejection. J Nephrothol. 2023;12(1):e18389. DOI: 10.34172/jnp.2022.18389.

Introduction

In 2019, the outbreak of coronavirus was reported to the World Health Organization (WHO). This pathogen can be transmitted to humans through respiratory droplets and causes severe acute respiratory syndrome (1).

It may have a severe clinical course, while some patients may experience no significant clinical symptoms (2). In COVID-19, an immune system response that does not work right could cause severe lung damage and other problems that lead to organ failure (3).

Since COVID-19 is spreading quickly and widely, there is a need to gather all possible information about the disease and report rare presentations, especially in other concurrent diseases, to help clinicians with best management (4).

We aimed to report a case report and share our experience in managing the patient to help clinicians better understand the risks of kidney transplant recipients.

Case Report

On December 9, 2020, a 27-year-old man with end-stage renal illness and hypertension got a kidney from a donor who had died. This was because he had IgA nephropathy. The patient had no specific past medical history. His

immunosuppressant plan was to take 12 mg of Prograf orally twice a day and 360 mg of Myfortic three times a day, and there were no signs of acute rejection.

Three days after transplantation, he was admitted to BueAli hospital in Shiraz, complaining of a high-grade fever (up to a maximum of 39.2°C) for two days. This fever was followed by a cough and shortness of breath. As recommended by the doctor, all of his immunosuppressants were decreased.

A chest computed tomography (CT) scan was conducted upon admission for him to rule out COVID-19, which showed ground-glass opacities in multiple areas of both lungs (Figure 1). Laboratory testing showed a mild decrease in white blood cell count and a decreased absolute lymphocyte count (1000/ μ L). One day after admission, serum creatinine rose to 7 mg/dL.

For detection of severe acute respiratory syndrome coronavirus 2 (SARS-CoV-2), A nasopharyngeal swab sample was collected and delivered to the laboratory. SARS-CoV-2 positivity, which was confirmed by real-time reverse transcription-polymerase chain reaction (RT-PCR) and CT results, led to the COVID-19 diagnosis for our patient. Methylprednisolone (40 mg daily) and remdesivir were used to start the combination therapy for two days

**Corresponding author:* Sahand Mohammadzadeh,
Email: mohammads@sums.ac.ir

to inhibit viral replication. Four days after admission, due to the rise of creatinine to 7 mg/dL, a renal biopsy was done to rule out delayed graft function or rejection. Renal biopsy revealed acute T cell-mediated rejection grade 2b due to arteritis in three vessels and moderate acute tubular injury with tubular necrosis (Figure 2).

His immunosuppressive regimen consisted of Prograf 12 mg orally twice daily and Myfortic 360 mg three times daily was resumed. High-flow nasal oxygen administration was ordered for him, and he underwent hemodialysis three times. During the clinical course, the patient's symptoms went away, his body temperature went down to 37.1°C, and his breathing problems like coughing and shortness of breath went away.

The lymphocyte count and serum creatinine improved. The kidney function also got better during therapy. On day 9, the second CT scan of the chest showed a significant improvement, and the ground-glass opacities on both sides got smaller.

The patient was released from the hospital on day 13 in consideration of the PCR's continued negative results on days 9 and 11, as well as the diminished lung lesions. To date, the patient follow-up has been in good health at home for four months.

Discussion

Due to taking large doses of immunosuppressive medications, kidney transplant recipients have a significant susceptibility to viral pneumonia (4). Here, we describe a COVID-19 instance in a recipient of a kidney transplant. The diagnosis was made based on the patient's symptoms and the results of a chest CT scan. The results of real-time PCR assays confirmed the diagnosis.

It is unknown how the COVID-19 pandemic may affect graft and patient outcomes in people who do not have COVID-19, although coronavirus-infected kidney transplant recipients have a considerable risk of graft loss and death (5).

When compared to the general population, immunosuppressive medications prescribed by nephrologists may enhance a patient's vulnerability to several viral infections with varying clinical presentations and therapeutic outcomes (6).

Although it has been observed in some research and has not gone unnoticed in COVID-19, the aetiology of acute renal injury is yet unknown. It has been proposed that the virus infects the parenchyma directly and causes microangiopathy through inflammatory responses (7).

There were only a few reports of acute rejection in COVID-19 patients in the literature (8). Coronavirus could cause rejection in people who have had a kidney transplant and have Coronavirus. Suggested explanations include low-dose immunosuppression or calcineurin

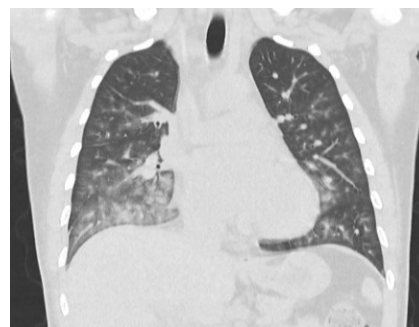


Figure 1. Multiple irregular ground-glass opacities were seen in the bilateral lungs on a computed tomography (CT) scan.

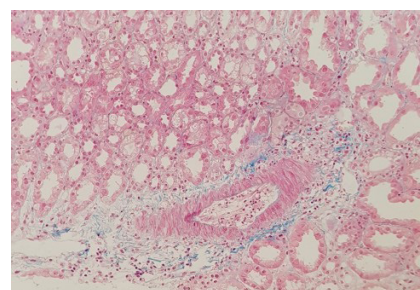


Figure 2. Renal biopsy results showed mild acute renal damage and acute T cell mediated rejection grade 2b as a result of vesicular arteritis (×100).

inhibitor toxicity due to drug-drug interactions (such as lopinavir or ritonavir) (9). However, due to the small number of studies, it is still unknown whether COVID-19's normal course causes transplant recipients to reject their organs or whether lowering their immunosuppressive dosage caused the disease to become more prominent (5).

Another option in our situation is that COVID-19 was really accidental because the patient was in the high risk category for contracting the disease and this was simply a case of severe rejection in the immediate post-transplant period.

We believe the reported case of a transplant patient who has COVID-19 is rare. There is a shortage of clinical information on transplant patients and the administration of immunosuppressive anti-rejection therapy for COVID-19 infection (9). Supportive care is the best management approach because there hasn't been a clear recommendation for therapeutic agents in COVID-19 up until now (10).

Our report of a COVID-19 infection in a renal transplant recipient with a successful outcome but differing clinical outcomes may act as a guidance for treating patients with this condition.

Authors' contribution

Conceptualization: SM.
 Methodology: NS.
 Validation: NS.
 Formal analysis: NN.
 Investigation: NS.
 Resources: SM.
 Data curation: NN.
 Writing—original draft preparation: SM.
 Writing—review and editing: SM.
 Visualization: NN.
 Supervision: SM.
 Project administration: SM.

Conflicts of interest

The authors declare that they have no conflicts of interest.

Ethical issues

This case report was conducted in accord with the World Medical Association Declaration of Helsinki. Patient has given us a written informed consent for publication as a case report. Ethical issues (including plagiarism, data fabrication, double publication) have been completely observed by the authors.

Funding/Support

No funding was used in this study.

References

1. Ning L, Liu L, Li W, Liu H, Wang J, Yao Z, et al. Novel coronavirus (SARS-CoV-2) infection in a renal transplant recipient: Case report. *Am J Transplant.* 2020;20:1864-1868. doi: 10.1111/ajt.15897.
2. Li J, Chen G, Zhang M, Tu S, Chen C. Different clinical presentations of two renal transplant recipients with coronavirus disease 2019: a case report. *BMC Infect Dis.* 2020;20:707. doi: 10.1186/s12879-020-05434-4.
3. Meziyerh S, Zwart TC, van Etten RW, Janson JA, van Gelder T, Alwayn IPJ, et al. Severe COVID-19 in a renal transplant recipient: A focus on pharmacokinetics. *Am J Transplant.* 2020;20:1896-901. doi: 10.1111/ajt.15943.
4. Li Q, Cheng Q, Zhao Z, Dai N, Zeng L, Zhu L, et al. Novel coronavirus infection and acute kidney injury in two renal transplant recipients: a case report. *J Int Med Res.* 2020;48:300060520964009. doi: 10.1177/0300060520964009.
5. Zhu L, Gong N, Liu B, Lu X, Chen D, Chen S, et al. Coronavirus Disease 2019 Pneumonia in Immunosuppressed Renal Transplant Recipients: A Summary of 10 Confirmed Cases in Wuhan, China. *Eur Urol.* 2020;77:748-754. doi: 10.1016/j.eururo.2020.03.039.
6. Zhu L, Xu X, Ma K, Yang J, Guan H, Chen S, et al. Successful recovery of COVID-19 pneumonia in a renal transplant recipient with long-term immunosuppression. *Am J Transplant.* 2020;20:1859-1863. doi: 10.1111/ajt.15869.
7. Johnson KM, Belfer JJ, Peterson GR, Boelkins MR, Dumkow LE. Managing COVID-19 in Renal Transplant Recipients: A Review of Recent Literature and Case Supporting Corticosteroid-sparing Immunosuppression. *Pharmacotherapy.* 2020;40:517-524. doi: 10.1002/phar.2410.
8. Cheng D, Wen J, Liu Z, Lv T, Chen JS. Coronavirus disease 2019 in renal transplant recipients: Report of two cases. *Transpl Infect Dis.* 2020;22:e13329. doi: 10.1111/tid.13329.
9. Kumar RN, Tanna SD, Shetty AA, Stosor V. COVID-19 in an HIV-positive kidney transplant recipient. *Transpl Infect Dis.* 2020;22:e13338. doi: 10.1111/tid.13338.
10. Hammami MB, Garibaldi B, Shah P, Liu G, Jain T, Chen PH, et al. Clinical course of COVID-19 in a liver transplant recipient on hemodialysis and response to tocilizumab therapy: A case report. *Am J Transplant.* 2020;20:2254-2259. doi: 10.1111/ajt.15985.

Copyright © 2023 The Author(s); Published by Society of Diabetic Nephropathy Prevention. This is an open-access article distributed under the terms of the Creative Commons Attribution License (<http://creativecommons.org/licenses/by/4.0>), which permits unrestricted use, distribution, and reproduction in any medium, provided the original work is properly cited.