

Journal of Nephropathology



Disseminated tuberculosis presenting as a crescentic glomerulonephritis

Gerry George Mathew^{1*}, Dinesh Babu²

¹Department of Nephrology, SRM Medical College Hospital and Research Centre, Chennai, Tamil Nadu, India-603203

²Department of General Medicine, Shree Balaji Medical College, Chennai, Tamil Nadu, India-6000044

ARTICLE INFO

Article type:
Photonephropathology

Article history:
Received: 14 January 2023
Accepted: 8 March 2023
Published online: 10 April 2023

ABSTRACT

A 48-year-old male patient presented with dialysis dependent renal failure with biopsy showing crescentic glomerulonephritis and Positron emission tomography–computed tomography (PET-CT scan) revealing features of pericardial, pulmonary tuberculosis with positive urinary GeneXpert test for tuberculosis bacilli. Clinicians should keep in mind the atypical presentations of tuberculosis while managing rapidly progressive renal failure especially in tropical countries with high prevalence of tuberculosis.

Keywords: Disseminated tuberculosis, Crescentic glomerulonephritis, Pleural fluid

Implication for health policy/practice/research/medical education:

Disseminated tuberculosis may manifest as rapidly progressive renal failure with crescentic glomerulonephritis on biopsy.

Please cite this paper as: Mathew GG, Babu D. Disseminated tuberculosis presenting as a crescentic glomerulonephritis. J Nephropathol. 2023;12(3):e21434. DOI: 10.34172/jnp.2023.21434.

Introduction

A 48-year-old male patient presented with drowsiness and breathlessness with history of low-grade fever with cough for one month. His serum creatinine – 10.7 mg/dL, urea – 226 mg/dL, hemoglobin – 9.3 g/dL, white blood count – 13600/ μ L, platelets – 172000/ μ L, serum protein – 6 g/dL and LDH (lactate dehydrogenase) was 290 IU/L. His chest X-ray showed left moderate pleural effusion and urine revealed 8-10 red blood cells/high power field and plenty of pus cells. His blood, sputum and urine culture revealed no growth. Pleural fluid analysis revealed 250 cells (60 %lymphocytes and 40 %polymorphs). Pleural fluid protein level was 3.4 g/dL and LDH was 240 IU/L, which was exudative as per Light's criteria. Pleural fluid adenosine deaminase (ADA) – 15 IU/L that was non-confirmatory of tuberculosis. Pleural fluid analysis for *Mycobacterium tuberculosis* by GeneXpert, (cartridge based nucleic acid amplification test; CBNAAT), bacterial and fungal organisms were negative by staining and culture methods. Additionally, anti-nuclear antibody (ANA), anti-double stranded DNA antibodies (anti-dsDNA) and antineutrophil cytoplasmic autoantibodies (ANCA) levels were negative. Meanwhile, serum C3 was 69.20 mg/dL (low) and C4 was 30.90 mg/dL (normal). After optimal dialysis, patient was subjected to renal biopsy, which

revealed cellular crescents in 12 glomeruli out of the sampled 16 glomeruli with endocapillary hypercellularity, focal neutrophilic influx and inflamed edematous interstitium (Figure 1).

Few circumferential cellular crescents completely compressed the glomerular tuft (Figure 2), and coarse granular C3(3+) (Figure 3) and IgG (2+) staining was visualized along the capillary walls on immunofluorescence.

Positron emission tomography–computed tomography (PET-CT) scan revealed metabolically active bilateral supraclavicular, para-aortic, para tracheal and hilar lymph nodes with diffuse pericardial thickening (Figure 4), pleural thickening across left posterior costophrenic recess and fluorodeoxyglucose avid bilateral kidneys.

Urine GeneXpert revealed positivity for *Mycobacteria tuberculosis* with rifampicin sensitivity. The patient started on isoniazid, rifampicin, levofloxacin on daily dose regimen, pyrazinamide on alternate days post-hemodialysis with steroids (0.5 mg/kg). The patient is still dialysis dependent; however, his fever and constitutional symptoms subsided with resolution of pleural effusion. This photo-clinic represents a rare manifestation of tuberculosis which bears resemblance to case reports of Kanodia et al (1) and Solak et al (2). The crescentic

*Corresponding author: Gerry George Mathew,
Email: gerrygeorge007@gmail.com, mathewgg@srmist.edu.in

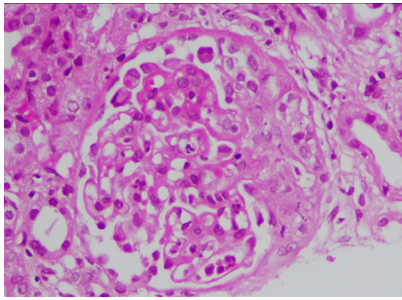


Figure 1. Haematoxylin and eosin slide showing glomerulus with endocapillary hypercellularity with focal neutrophilic influx with cellular crescent.

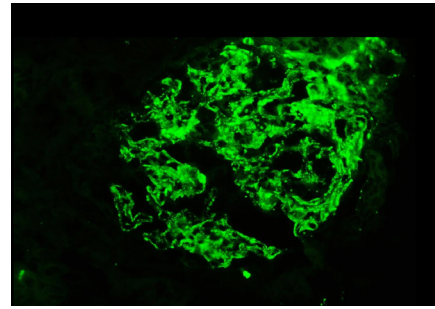


Figure 3. Immunofluorescence showing coarse granular positivity of C3 along the glomerular capillary loops.

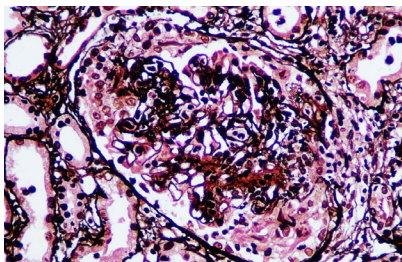


Figure 2. Jones methenamine silver stain showing cellular crescent engulfing the glomerular tuft.

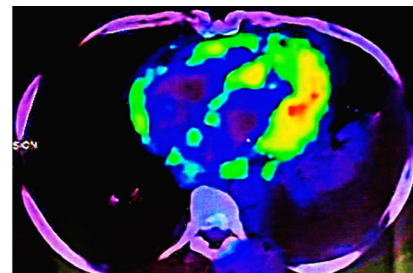


Figure 4. PET CT scan revealing metabolically active diffuse pericardial thickening with effusion.

presentation of glomerulonephritis in tuberculosis portends grave prognosis with increased mortality and poor renal outcome (1).

Acknowledgements

We acknowledge Dr. Anila Abraham Kurien for her renal pathology interpretation and renal biopsy pictures.

Authors' contribution

Conceptualization: GGM.

Methodology: GGM and DB.

Validation: GGM and DB.

Formal analysis: GGM.

Investigation: GGM.

Resources: GGM and DB.

Data curation: GGM.

Writing—original draft: GGM.

Writing—review and editing: GGM and DB.

Visualization: GGM and DB.

Supervision: GGM.

Project administration: GGM.

Funding acquisition: GGM.

Conflicts of interest

The authors declare no conflicts of interest

Ethical issues

This photo-clinic was done in accordance with the Declaration of Helsinki. Written informed consent was obtained from the patient before publication. Ethical issues (including plagiarism, data fabrication, double publication) have been completely observed by the authors.

Funding/Support

None.

References

1. Kanodia KV, Vanikar AV, Patel RD, Suthar KS, Trivedi HL. Crescentic glomerulonephritis associated with pulmonary tuberculosis. *J Clin Diagn Res.* 2016;10:ED01-2. doi: 10.7860/JCDR/2016/14191.6970
2. Solak Y, Gaipov A, Anil M, Atalay H, Ozbek O, Turkmen K, et al. Glomerulonephritis associated with tuberculosis: a case report and literature review. *Kaohsiung J Med Sci.* 2013;29:337-42. doi: 10.1016/j.kjms.2012.10.008.