

Journal of Nephropathology

Dermatological diseases in patients with chronic kidney disease

Amy L. Gagnon¹, Tejas Desai^{2,*}

¹Department of Internal Medicine, East Carolina University, Greenville, North Carolina, United States of America.

²Division of Nephrology and Hypertension, East Carolina University, Greenville, North Carolina, United States of America.

ARTICLE INFO

Article type:
Short Review Article

Article history:
Received: 1 December 2012
Accepted: 15 December 2012
Published online: 1 April 2013

Keywords:
Chronic kidney disease
Malignancy
Dermatological diseases
Renal transplantation

ABSTRACT

Context: There are a variety of dermatological diseases that are more commonly seen in patients with chronic kidney disease (CKD) and renal transplants than the general population.

Evidence Acquisitions: Directory of Open Access Journals (DOAJ), Google Scholar, Pubmed (NLM), LISTA (EBSCO) and Web of Science has been searched.

Results: Some cutaneous diseases are clearly unique to this population. Of them, Lindsay's Nails, xerosis cutis, dryness of the skin, nephrogenic systemic fibrosis and acquired perforating dermatosis have been described in chronic kidney disease patients. The most common malignancy found in all transplant recipients is non-melanoma skin cancer.

Conclusions: It is important for patients and physicians to recognize the manifestations of skin disease in patients suffering from chronic kidney disease to mitigate the morbidity associated with these conditions.

Implication for health policy/practice/research/medical education:

There are a variety of dermatological diseases that are more commonly seen in patients with chronic kidney disease and renal transplants than the general population. Some cutaneous diseases are clearly unique to this population. It is important for patients and physicians to recognize the manifestations of skin disease in renal disease to minimize and even prevent much of the morbidity associated with these conditions.

Please cite this paper as: Gagnon AL, Desai T. Dermatological diseases in patients with chronic kidney disease. J Nephropathology. 2013; 2(2): 104-109. DOI: 10.12860/JNP.2013.17

1. Context

There are a variety of dermatological diseases that are more commonly seen in patients with chronic kidney disease (CKD) and renal transplants than the general population. Some cutaneous diseases are clearly unique to this population. It is important for patients and physicians to recognize the manifestations of skin disease in renal disease to minimize and even

prevent much of the morbidity associated with these conditions.

2. Evidence Acquisition

Directory of Open Access Journals (DOAJ) Google Scholar, Pubmed (NLM), LISTA (EBSCO) and Web of Science were searched with key words relevant to chronic kidney disease, malignancy, dermatological diseases and renal trans-

**Corresponding author:* Dr. Tejas Desai, Division of Nephrology and Hypertension, East Carolina University, Greenville, North Carolina, United States of America. Tel=+1 252-744-1380, Fax:....., Email: desait@ecu.edu

plantation.

3. Results

Important skin manifestations are as follow:

3.1. Half & Half Nails

Half and half nails, also called Lindsay's Nails, are said to be found in as many as 21% of patients on dialysis(1). They appear as a discoloration of the nail with a proximal white portion and a distal reddish-pink to brown portion (Figure 1) (1). The discoloration does not change with nail growth, indicating the problem begins in the nail bed. The discoloration also does not fade with pressure. The exact pathophysiological mechanism associated with half and half nails is not understood, but an increase in the number of capillaries and capillary wall thickness has been observed in the nail bed (2). It can be found at any level of azotemia, and does not improve with dialysis; however, it does sometimes improve (and even disappear) with kidney transplantation (3,4).

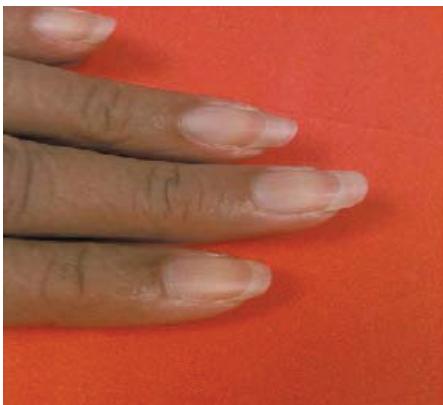

Figure 1. Discoloration of the nail with a proximal white portion and a distal reddish-pink to brown portion (From Markova A, Lester J, Wang J, Robinson-Bostom L. Diagnosis of common dermatopathies in dialysis patients: A review and update. *Semin Dial.* 2012;25(4):408-418, with permission)

3.2. Xerosis

Xerosis cutis, dryness of the skin, is one of the most common skin conditions seen in chron-

ic renal failure (4). It has been reported to affect 50-85% of patients on maintenance dialysis (5). It is usually found over the extensor surfaces of the forearms, legs, and thighs (Figure 2) (1). It is caused by reduction in the size of eccrine sweat glands and atrophy of sebaceous glands. Use of diuretics has also been implicated (1,6). Treatment of xerosis involves behavioral changes and use of topicals. Patients should be advised not to shower excessively, as the dry skin can be irritated by accumulation of soap. They should also apply daily emollients to moist or wet skin (5). Urea 10% lotion with dexpanthenol has also been shown to decrease scaling and redness in xerosis (7).

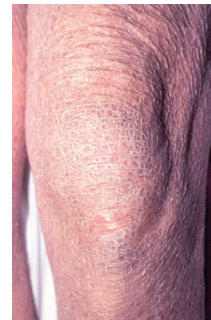


Figure 2. Xerosis cutis, dryness of the skin (From Phillips, C. East Carolina University Department of Dermatology, with permission)

3.3. Nephrogenic systemic fibrosis

Nephrogenic systemic fibrosis (NSF) is a rare, systemic fibrotic disorder found uniquely in renal failure. It is characterized by visible fibrosis of the skin consisting of hardened, thickened, tethered, hyperpigmented and/or shiny changes (Figure 3) (8). Fibrotic skin across joints leads to flexion contractures and immobility (9). Sclerotic changes are noted most frequently in the feet, ankles, shins, thighs, fingers, hands, and lower arms (8). Nearly all known cases of NSF occur in patients with exposure to gadolinium contrast-enhanced MRI or MRA within 2-3 months of symptom onset (9). The absolute risk of NSF in

a patient with any gadolinium agent exposure has been reported to range 1.13-3.4%, making it a rare entity (4). To diagnose NSF, a scoring system of clinical and histopathological criteria has been used. Several pathophysiological mechanisms have been proposed, and it appears to be related to increased collagen deposition, with fibrosis occurring in multiple organ systems, including the lungs, heart, and liver (9). Unfortunately, there is also no effective treatment for NSF. Topical or systemic corticosteroids, cyclophosphamide, thalidomide, plasmapheresis, immunoglobulin infusion, imatinib mesylate, and rapamycin have been reported to offer some improvement. Prevention of this disease is most important, including avoidance of triggers. Gadolinium agents should only be used in patients in ESRD when absolute necessary (4).

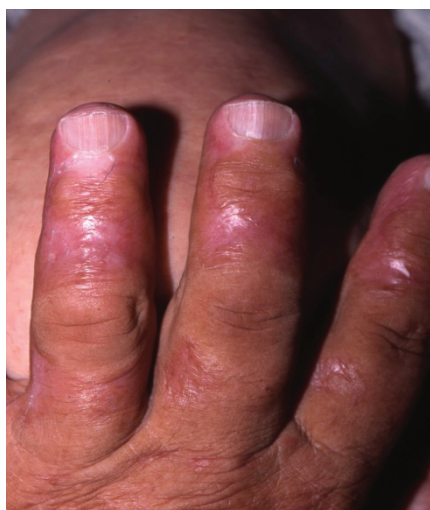

Figure 3. Nephrogenic systemic fibrosis (NSF) [From Phillips, C. East Carolina University Department of Dermatology, with permission].

3.4. *Acquired perforating disease of hemodialysis*

Acquired perforating dermatosis (APD) describes a group of disorders with transepidermal elimination of collagen, elastic tissue, or necrotic connective tissue acquired in adulthood. These patients have systemic diseases such as diabetes mellitus and renal failure, including dialysis (10).

A subset of APD, acquired perforating dermatosis of hemodialysis is characterized by hyperkeratotic papular lesions (Figure 4). They occur predominantly on the trunk and extensor limb surfaces (2). The incidence in North America ranges between 4.5-10% of patients receiving chronic hemodialysis, however, APD in ESRD has been reported in transplant recipients, and in CKD patients not yet on dialysis, as well (2,11). Although the exact pathophysiological mechanism for APD in ESRD is unknown, it is thought to be the result of dermal connective tissue dysplasia and decay (11). Local trauma and necrosis of the dermal changes layer may be secondary to trauma to the skin induced by frequent scratching by patients with pruritus from CKD (1,12). The lesions of APD may resolve spontaneously. When treatment is desired, topical retinoids, topical and intradermal steroids, and UVB light have been tried with variable results (1).

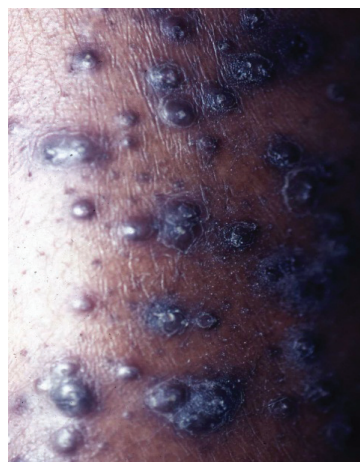

Figure 4. Acquired perforating dermatosis (From Phillips, C. East Carolina University Department of Dermatology, with permission).

3.5. *Non-melanoma skin cancer*

The most common malignancy found in all transplant recipients is nonmelanoma skin cancer (NMSC), and the incidence is approximately 2.2% in renal transplants, according to one study (13). This increased incidence of NMSC is caused by

immunosuppression, and the incidence of NMSC is up to 20-fold greater in renal transplant recipients when compared to the general population (13). Of the two most common NMSC histological types, squamous cell carcinoma (SCC) is typically more aggressive, recurrent, and metastatic than basal cell carcinoma (BCC). SCC also happens to be more common in the renal transplant population (Figure 5). Localization of this cancer to sun-exposed skin, including the head and face can require complex surgical procedures (14). Risk factors for NMSC's in renal transplant patients include dosage and duration of immunosuppression, older age (>55 years), male sex, white skin, history of skin cancer prior to transplantation, lower peak panel reactive antibody (PRA) level, and less-well defined genetic factors.¹⁶ High risk patients and clinicians should have a high suspicion for NMSC in their transplant patients, and be especially aware of pre-malignant skin lesions as well, including Bowen's disease (in situ SCC) and actinic keratosis. Full-body skin examination can help to identify these lesions early. Patients should be taught to routinely perform self-examinations, and full body skin checks should be incorporated into regular post-transplant follow up appointments (13).

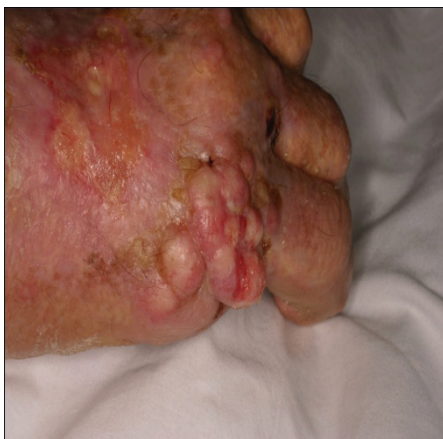

Figure 5. Non-melanoma skin cancer (From Phillips, C. East Carolina University Department of Dermatology, with permission).

3.7. Access Site Infections

As the number of ESRD patients grows, so does the need for various hemodialysis access sites. Unfortunately, infections are second only to coronary artery disease as a cause for mortality in the ESRD population. Vascular accesses are responsible for 48-73% of all bacteremias in hemodialysis patients (15). One study of hemodialysis patients with multiple access types found that hemodialysis catheters have the highest risk of infection, followed by grafts, and lastly, native vessel fistulas (Figure 6) (16). A patient with ESRD is, in a sense, immunosuppressed, with disrupted host defenses, including depressed neutrophil function, leukopenia related to complement activation, impaired phagocytosis, diminished T and B lymphocyte function, and reduced natural killer cell activity (11). This makes them even more susceptible to infection, and frequent cannulation increases the likelihood of contamination. Prevention of access infections requires a dialysis staff committed to policy and procedure adherence. OSHA regulations for dialysis staff include strict hand washing between patients and the use of clean gloves during needle cannulation. Additionally, asking patients to wash their access arms with soap and water decreases the skin's microflora, and can potentially decrease the incidence of bacterial introduction into the bloodstream with cannulation (11). Nurses, doctors, and patients should be aware that patients may not have fever or elevated white blood count with an access infection. Any change to the appearance of an access, ie. new lesion on the surface, induration, or inflammation, warrants a more extensive evaluation, not limited to blood cultures and complete blood count (11).

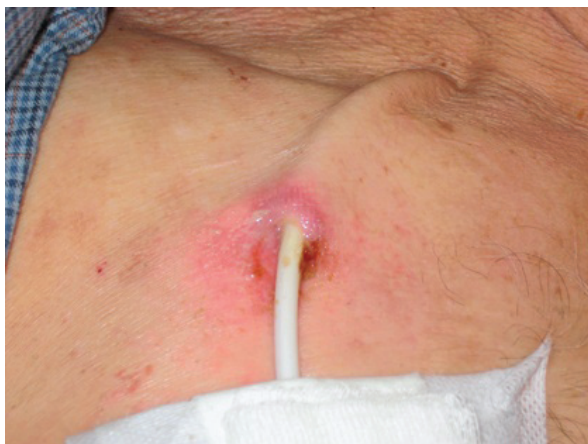

Figure 6. Access site infection (From Lok CE, Mokrzycki MH. Prevention and management of catheter-related infection in hemodialysis patients. *Kidney Int.* 2011; 79(6):587-598, with permission).

4. Conclusions

As the treatment of renal disease advances, and CKD patients are living longer and more fulfilling lives, the incidence of cutaneous disease in these patients will likely increase as well. Awareness of the cutaneous manifestations facing this population of patients is especially important, as prevention and early treatment can enhance many lives.

Authors' Contribution

ALG drafted the manuscript and performed the literature search. TD provided critical revisions of the manuscript.

Conflicts of interest

Neither ALG nor TD have any conflicts to disclose.

Funding/Support

There was no funding for this manuscript.

References

1. Udayakumar P, Balasubramanian S, Ramalingam KS, Lakshmi C, Srinivas CR, Mathew AC. Cutaneous manifestations in patients with chronic renal failure on hemodialysis. *Indian J Dermatol Venereol Leprol.* 2006;72(2):119-25.

2. Kurban MS, Boueiz A, Kibbi AG. Cutaneous manifestations of chronic kidney disease. *Clin Dermatol.* 2008;26(3):255-64.
3. Alston H, Burns A. Half and half nails. *Nephrol Dial Transplant. NDT Plus.* 2011;4(5):361.
4. Markova A, Lester J, Wang J, Robinson-Bostom L. Diagnosis of common dermatopathies in dialysis patients: a review and update. *Semin Dial.* 2012;25(4):408-18.
5. Szepietowski JC, Balaskas E, Taube KM, Taberly A, Dupuy P. Quality of life in patients with uraemic xerosis and pruritus. *Acta Derm Venereol.* 2011;91(3):313-7.
6. Avermaete A, Altmeyer P, Bacharach-Buhles M. Skin changes in dialysis patients: a review. *Nephrol Dial Transplant.* 2001;16(12):2293-6.
7. Castello M, Milani M. Efficacy of topical hydrating and emollient lotion containing 10% urea ISDIN(R) plus dexpanthenol (Ureadin Rx 10) in the treatment of skin xerosis and pruritus in hemodialyzed patients: an open prospective pilot trial. *G Ital Dermatol Venereol.* 2011;146(5):321-5.
8. Elmholdt TR, Pedersen M, Jorgensen B, Sondergaard K, Jensen JD, Ramsing M, et al, editor(s). Nephrogenic systemic fibrosis is found only among gadolinium-exposed patients with renal insufficiency: a case-control study from Denmark. *Br J Dermatol.* 2011;165(4):828-36.
9. Haemel AK, Sadowski EA, Shafer MM, Djamali A. Update on nephrogenic systemic fibrosis: are we making progress? *Int J Dermatol.* 2011;50(6):659-66.
10. Wong J, Phelps R, Levitt J. Treatment of acquired perforating dermatosis with cantharidin. *Arch Dermatol.* 2012;148(2):160-2.
11. Headley CM, Wall B. ESRD-associated cutaneous manifestations in a hemodialysis population. *Nephrol Nurs J.* 2002;29(6):525-7.
12. Hari Kumar KV, Prajapati J, Pavan G, Parthasarathy A, Jha R, Modi KD. Acquired perforating dermatoses in patients with diabetic kidney disease on hemodialysis. *Hemodial Int.* 2010;14(1):73-7.
13. Zavos G, Karidis NP, Tsourouffis G, Bokos J, Diles K, Sotirchos G, et al. Nonmelanoma skin cancer after renal transplantation: A single-center experience in 1736 transplantations. *Int J Dermatol.* 2011;50(12):1496-500.
14. Tessari G, Naldi L, Boschiero L, Minetti E, Sandrini S, Nacchia F, et al. Incidence of primary and second cancers in renal transplant recipients: a multicenter cohort study. *Am J Transplant.* 2012;13(1):214-21.
15. Nassar GM, Ayus JC. Infectious complications of the

hemodialysis access. *Kidney Int.* 2001;60(1):1-13.

16. Hoen B, Paul-Dauphin A, Hestin D, Kessler M. EPI-BACDIAL: a multicenter prospective study of risk factors for bacteremia in chronic hemodialysis patients. *J Am Soc Nephrol.* 1998;9(5):869-76.