

Journal of Nephrothology

CrossMark
click for updates

Evaluation of mandibular inferior cortex changes in patients candidate for liver and kidney transplantation using panoramic view

Jannan Ghapanchi¹, Abdul Aziz Haghnegahdar^{2*}, Maryam Faghih³, Fahimeh Rezazadeh¹, Reza Derafshi⁴, Mitra Farzin⁴, Mohamad Hassan Kalantari⁴

¹Department of Oral & Maxillofacial Medicine, Shiraz University of Medical Sciences, Shiraz, Iran

²Department of Oral & Maxillofacial Radiology, Shiraz University of Medical Sciences, Shiraz, Iran

³Student Research Committee, Shiraz University of Medical Sciences, Shiraz, Iran

⁴Department of Prosthodontics, School of Dentistry, Shiraz University of Medical Sciences, Shiraz, Iran

ARTICLE INFO

Article type:
Original Article

Article history:
Received: 14 November 2016
Accepted: 7 April 2017
Published online: 12 May 2017
DOI: 10.15171/jnp.2017.51

Keywords:
Chronic kidney disease
Chronic liver disease
Inferior mandibular cortex
Panoramic radiography
Transplant
Bone density

ABSTRACT

Background: The number of patients with chronic liver failure (CLF) or chronic kidney disease (CKD) referred to dental clinics are increasing. However, there are few studies about the effect of these diseases on jaw bones.

Objectives: The aim of this study was to evaluate the inferior mandibular cortex changes of the patients with CLF and CKD that are candidate for liver and kidney transplantation, in panoramic views.

Patients and Methods: Panoramic radiographs were obtained from 83 patients with a history of CLF and 43 patients with CKD who were undergoing the assessment for transplantation and also 126 control cases. The mean was calculated for the width of inferior mandibular cortex. The relationship between the thicknesses of the inferior mandibular cortex with the duration of disease was determined using Pearson's correlation coefficient test. T and chi-square tests were used for evaluating the inferior cortex of the mandible according to age and sex, respectively.

Results: Compared with the control group, the means of the cortical thickness in CLF and CRF patients were significantly different ($P < 0.001$). There was a significant relationship between cortical thickness and gender in CLF ($P = 0.007$) and CRF patients ($P = 0.029$). Neither the duration of the disease and nor age was associated with mandibular thickness changes in CLF and CRF patients ($P = 0.79$). Thickness of the inferior mandibular cortex in premolar area was more than that in molar area and thickness of molar was greater than that of the mandibular angle in CKD and CLF patients. This latter was similar to that in normal subjects.

Conclusion: Compared with normal population, a decrease in the thickness of inferior mandibular cortex is observed in CKD and CLF patients. This decrease is not affected by age and duration of the disease but is meaningfully related to sex, especially females.

Implication for health policy/practice/research/medical education:

Radiographic changes of the mandible (jaw bone) could be interpreted as a sign of osteopenia that may be an important finding in kidney and liver diseases. This may be affected dental procedure.

Please cite this paper as: Ghapanchi J, Haghnegahdar AA, Faghih M, Rezazadeh F, Derafshi R, Farzin M, et al. Evaluation of mandibular inferior cortex changes in patients candidate for liver and kidney transplantation using panoramic view. J Nephrothol. 2017;6(4):317-323. DOI: 10.15171/jnp.2017.51.

1. Background

The number of patients with chronic liver failure (CLF) or chronic kidney disease (CKD) referred to dental clinics are on the increase (1). These patients, who are candidates for liver and kidney transplant, must be continuously evaluated by a dentist prior to the

procedures. Infectious complication is one of the most important causes of morbidity and mortality in liver and kidney transplant recipients. Systemic infections subsequent to oral infection were seen in both liver and kidney transplant candidates and recipients. Susceptibility to oral infection increased prominently

*Corresponding author: Abdul Aziz Haghnegahdar, Email: ahagh@sums.ac.ir

in patients undergoing liver or kidney transplant, thus preventive measures are necessary. Most of these cases can receive routine dental care but an written accepted protocol is not available yet (1,2).

As after transplantation, immunosuppressive drug suppresses the immunity of the patients, the spread of any infection can be life threatening. Carious lesion and periodontal pockets intrude microorganisms and release toxins into the bones of the jaws, which may be restricted to the periapical area by defense mechanism of bone, producing no sign or symptom. If these lesions remained in the jaw, they can be activated after transplantation with disastrous consequences. Some authors maintain that brain and liver pyogenic abscess maybe related to oral infections (3-5).

Elimination of all infection centers before transplanting patients is mandatory. Dentists are responsible for the eradication of any active or potential foci of infection in the mouth of such patients. They must restore all treatable teeth and any questionable and/or untreatable tooth should be extracted to ensure no risk of infection spread after transplantation. Beside the teeth, bones are also in paramount importance and should be evaluated completely. Changes in bone metabolism, caused by kidney and liver diseases, lead to osteopenia (6,7).

Unhealthy and osteopenic bone is more vulnerable to chemical, physical and infective insults and more destruction is expected in these cases (6,7). In addition to dental aspects, bone status is important to other branches of medicine in order to eliminate or reduce complications such as fractures or dysfunctions and pain (1-3).

Panoramic radiographs are extensively used in routine dental examinations. They employ a relatively low dose technique which covers a large area of skull, including all teeth, both jaws and surrounding bones. This technique is accessible, cheap, and easy to perform, understand and interpret (8).

Since a large amount of bones is visualized in panoramic view, it may be used as a screening radiograph for evaluating the bone changes by expert physicians.

Osteolytic changes of many diseases have been traced in panoramic views in many studies and the efficacy of these graphs for primary bone evaluation is confirmed. The bony changes in panoramic views may be considered as an encouraging sign for more detailed and specific bone evaluation to prevent serious consequences as much as possible.

Researchers estimate that oral symptom will be shown in more than 90% of patients with CRF which could be evaluated clinically or radiographically (9). Oral mucosa, teeth, salivary gland and jaw bone may be affected (10). Most of changes may be detected in panoramic views. One of the most important complications of CLF is osteodystrophy which results to bone fragility and

increased incidence of bone fractures, leading to pain and long lasting immobility and deformity (11).

In this regards, Bras et al found that panoramic radiograph of patients with CRF represent a lack of cortical bone at the mandibular angle (12). Bandeira et al reported that periodontal disease progression, absence of lamina dura, deviations in trabecular pattern and brown tumor can be found in patients who receiving hemodialysis (13). In another study, 58% of cases on hemodialysis, showed abnormalities in maxilla and mandibular bone such as; osteoporosis, loss of lamina dura or reduction in lamina dura thickness, brown tumor and focal osteosclerosis adjacent to tooth roots (14). A radiographic study in 40 patients with chronic renal failure, showed a consequential reduction between skeletal changes and reduction in lamina dura thickness and trabecular pattern (15). Shakibaei et al, observed alteration in trabecular pattern and changes in jaw bone density (16). The frequency of bone disease in cirrhotic patients was reported to be 12% to 55% by Patel et al (17). In the study by Dagistan et al, pathologic defects with ground-glass appearance were seen in the mandible (18).

Although many aspects of CKD and CLF have been searched, there are few studies about the effect of these diseases on jaw bones in literature. Since inferior mandibular cortex is used as an index in osteoporosis especially in dental radiographies (19), this study is designed to assess the effect of CRF and CLF on the inferior mandibular cortex on panoramic views of patients. If significant relationship is discovered, this dental radiograph may be used as a sign for evaluating the bone status of the patients with CKD or CLF.

2. Patients and Methods

2.1. Study group

This analytical cross-sectional study was conducted on 252 panoramic views consisting of 126 CKD and CLF patients candidates for kidney or liver transplant (57 females, 69 males, aged between 20-70 years) and 126 healthy ones (47 females, 79 males, aged between 18-70 years old). All patients had been referred to the dental clinic (Shiraz, dental school Shiraz-Iran) for pretransplant oral examination. A control group (healthy people), with matched age and sex, that visited the same clinic for routine dental care between 2015 and 2016 was retrieved to determine the thickness of inferior mandibular cortex. After obtaining a written-informed consent, radiographs with acceptable quality from dentate patients entered the study. Patients with metabolic bone disease (thyroid disease, hyperparathyroidism and cushing disease), history of radiotherapy, anemia, corticosteroid medication and a history of smoking were excluded from the study. Demographic data including sex, age and duration of

their disease were registered.

2.2. Imaging procedures

Panoramic views were prepared by a Planmeca XC Proline panoramic machine (Helsinki, Finland). Exposure factors were adjusted according to the size and age of the patients (57-85 kVp, 10 mA), using Agfa PSP receptors (Germany). The images were observed on a Barco monitor (China) in a semi-darkened room. All radiographs were evaluated by an oral and maxillofacial radiologist and a last year student.

2.3. Measurements

Drawing a tangent line with inferior border of mandible, cortical thickness was measured on three reference points (along with the apices of second premolar (S1), second molar (S2) and the middle of the coronoid process and the condyle (S3) on both left and right sides using marking gauge in Agfa program (Figure 1). The mean of measured three thicknesses was mentioned as the final value.

2.4. Ethical considerations

The research followed the tenets of the Declaration of Helsinki. Written informed consent was obtained from all patients who participated in the study. All information about individuals was coded and kept confidential. This study was approved by the Ethics Committee of Shiraz University of Medical Sciences.

2.5. Statistical analysis

All data were collected and analyzed using SPSS software (version 18; SPSS Inc., Chicago, IL, USA). The Pearson's correlation coefficient test was used in order to determine the relationship between mandibular cortical thickness and duration of disease. Student's *t* test was performed to show the relation between age groups and mandibular cortical thickness. To compare the three index points, repeated measure analysis of variance (ANOVA) test was employed. The mean of the mandibular cortical thickness in all groups (kidney, liver and control) was evaluated by one-way ANOVA and Tukey test and $P < 0.05$ was accepted as significant.

3. Results

A total of 43 CKD patients (27 males and 16 females), with end-stage renal disease undergoing maintenance dialysis, were entered to the study. The patients ranged in age from 20 to 70 years old. The duration of dialysis ranged from one to 96 months with a median duration of 23.2 ± 27.41 months. Totally, 83 patients with CLF consisting of 53 men and 30 women, aged between 8 and 68 years, participated in the study. Duration of their disease was between 2 and 216 months with a

medium duration of 51.1 ± 63.25 months. One hundred twenty-six healthy controls (79 males and 47 females with the age range of 8-70) were also recruited in the study. Descriptive statistics for age and sex variables are showed in Table 1. In CKD patients, the mean of the thickness of inferior mandibular border was 2.67 ± 0.54 mm, for CLF group the amount was 2.77 ± 0.52 mm and for the control group was 3.38 ± 0.43 mm. The mean of the cortical thickness was significantly different in patients and controls ($P < 0.001$) (Table 2).

There was no significant difference between kidney and liver groups in thickness of inferior mandibular cortex. Statistical analysis did not show a significant correlation between the length of the disease and the cortical changes in CKD patients ($P = 0.28$, $r = 0.19$) and CLF patients ($P = 0.79$, $r = 0.03$).

There was statically significant relationship between cortical thickness and sex. The mean of cortical thickness in males of the CLF group was 2.87 ± 0.55 mm and in females was 2.61 ± 0.41 mm. In male CKD group, the mean of cortical thickness was 2.85 ± 0.45 mm and in females, it was 2.4 ± 0.56 mm. The mean of cortical thickness in females and males of the healthy

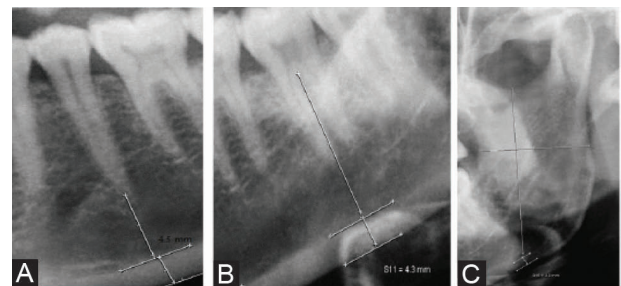


Figure 1. The measurements: (A) along with the apices of second premolar, (B) second molar, (C) the middle of the coronoid process and the condyle.

Table 1. Demographic variables between cases and controls

	Groups			P
	Liver, No. (%)	Kidney, No. (%)	Control, No. (%)	
Sex				0.933
Female	30 (36.1)	17 (39.5)	47 (37.3)	
Male	53 (63.9)	26 (60.5)	79 (62.7%)	
Age (Mean \pm SD)	45.60 \pm 14.20	50.58 \pm 14.18	46.51 \pm 14.28	0.174

Table 2. The mean of cortical mandibular thickness in cases and control groups

	Groups			P
	Liver	Kidney	Control	
Thickness of inferior mandibular cortex (Mean \pm SD)	2.77 \pm 0.52 ^a	2.67 \pm 0.541 ^a	3.38 \pm 0.43 ^b	<0.001

^{a,b}The different letters showed a significant correlation between CLF, CRF and the control group.

Table 3. Comparing the mean of cortical mandibular thickness in different groups according to age and sex

	Mean of cortical thickness		
	Liver group	Kidney group	Control group
Age (y)			
≤40	2.63±0.57	2.8±0.55	3.41±0.56
>40	2.84±0.48	2.63±0.543	3.37±0.38
<i>P</i> value	0.104	0.397	0.680
Sex			
Female	2.61±0.41	2.4±0.56	3.27±0.43
Male	2.87±0.5	2.85±0.45	3.44±0.44
<i>P</i> value	0.029	0.007	0.099

group showed no significant differences (Table 3). Comparing all three points together, statistical analysis showed that S1 (3.66 ± 0.04 mm) had the maximum thickness, followed by S2 (3.04 ± 0.03 mm) and S3 (2.15 ± 0.03 mm) (in three groups $P < 0.001$). There was no significant interaction effect between groups and measurement ($P = 0.135$). This means that the changes in thickness were similar among groups.

4. Discussion

The incidence of chronic renal failure continues to rise worldwide. Data on the epidemiology of CRF are available in many countries. Incidence of CKD is 377 per million in the United States. CKD increases with age and males are more commonly affected than females (18). The dialysis patient's number in Iran is almost 13 000 and the renal transplant patient's number is almost 17 000. In addition, it is estimated that yearly 1500 people will be added to the group of dialysis patients (16).

Chronic liver disease is a major cause of morbidity and mortality worldwide. The prevalence rates for CLF in the United States have been 11.78% (1988-1994), 15.66% (1999-2004) and 14.78% (2005-2008) (20). The number of pediatric liver transplantation undertaken in the United States has increased dramatically in recent years. The survival of these patients approaches 80%-90% at 1 year and 64%-78% at 5 years (21). Elimination of dental infection foci has been recommended before liver transplantation because lifelong immunosuppression may predispose to infection spread. Bone disease is a major complication of chronic liver disease and contributes to the morbidity, poor quality of life. It also negatively impinges upon the survival of patients with chronic liver disease and those waiting for or who have received a liver transplant. Osteoporosis which is quite common, occurring in up to 50% of patients, may result in spontaneous or low impact fractures in patients with chronic liver disease, adversely affecting morbidity, quality of life and survival (22). CLF patients commonly have low weight and malnutrition. One of the risk factor for osteoporosis is lower weight or bone mineral index (BMI). It is hypothesized that adipocyte

produced and released leptin which play a key role in bone metabolism regulation. This product increases proliferation of osteoblast, bone matrix synthesis and consequently increased bone formation. Leptin also causes to receptor activator of nuclear factor kappa-B ligand (RANKL) production inhibition and diminishing bone resorption. Patients with cholestatic liver disease also show decreased leptin levels (23-25). The prevalence of bone fractures was 20.8% in primary biliary cirrhosis patients (26). The prevalence of osteoporosis in patients with cirrhosis is between 12% and 55% (27). It is reported that the low bone mass density was an important risk factor for fracture (28).

End-stage renal disease results in some pathological changes in different organs. Between them, noticeably, bone changes are prominent and refer to renal osteodystrophy (16). Approximately, 90% of CKD cases are involved in jaw bone changes (10). Bone anomalies in CKD patients reflect the defect in metabolism of calcium which results in secondary hyperparathyroidism. This problem is seen in up to 92% of patients under hemodialysis (29).

Most authors in the field of organ transplantation agree that teeth with obvious infections, and all non-restorable teeth, must be extracted prior to transplantation. Therefore, patients should be reminded of earlier dental treatment and the importance of good oral hygiene habits (30). Owing to oral complications, these patients require to visit a dentist before and after transplantation (10).

Dental panoramic radiographs have a long history of radiological exam in dentistry. Jawbones and related structures have been shown in recent clinical studies to play a critical role in the identification and evaluation of patients with low bone mineral density (9). It is worthy of mention that the panoramic X-ray is used in the routine of all the types of dental patients (14). Radiographic changes of the mandible could be interpreted as a sign of osteopenia. It also appears to be a reliable tool for osteoporosis screening. The mandibular cortical width, which can be measured in panoramic radiography, may help to diagnose osteoporosis in postmenopausal women (31).

The current study aimed at evaluating the thickness of mandibular cortex in CKD and CLF patients using panoramic view. To the best knowledge of authors, there is no absolutely similar study in literature. To compare the results, having studied other aspects of CKD and CLF, the researchers have reported the most near ones: Bras et al found a loss of cortical bone at the mandibular angle in panoramic view of CKD patients. In the present study, we also found this loss of mandibular cortical thickness (12).

In a study conducted in Iran in 2001, a significant

relationship was found between age and cortical changes in CKD patients. Furthermore, males were reported to be more commonly affected than female. Our study evaluated relationship between mandibular cortical thickness and other variables, including sex, and age (32). Similarly, in our study, males showed a more prevalence of CKD, but we found no significant relationship between age and cortical changes in patients. The difference may be attributed to observers (i.e., general radiologist in that study and maxillofacial radiologist in our study) and to radiographs which were digital panoramic in the present study.

Queiroz et al evaluated the oral condition of patients with CKD undergoing dialysis and determined the influence of dialysis duration and bone metabolism on the prevalence and severity of the alterations. No significant correlation was observed between dialysis duration, biochemical alteration and oral health (33). These findings are compatible with our results, although we focused on bony changes of mandible.

Shakibaei et al, found that the relationship between lamina dura changes and duration of dialysis was not significant. Also she noticed a significant relationship between the patterns of bone trabecular and sex in patients (16). Similarly our research showed no relationship between the duration of dialysis and cortical changes, but there was a significant relationship between sex and cortical changes.

Dagistan et al found a significant decrease in antegonial index, gonial cortical bone thickness, and gonial angle values in chronic renal failure patients. Additionally, mandibular canal wall resorption was also statically significant (18). Similarly, in this study we found a significant difference between cases and controls in mandibular cortical thickness.

Likewise, Monegal et al measured bone mass of the lumbar spine and femur by dual x-ray absorption. They showed a significant decrease in bone mass, particularly in the lumbar spine, in end stage cirrhotic patients. They also found reduced bone formation and significant disorders of bone mineral metabolism in liver patients (34). Similarly, we found a decrease in bone tissues detected as the reduction of mandibular cortical thickness.

Accordingly, George et al detected patients with liver cirrhosis have low BMD (35), which can be interpreted to be in line with the findings of our study. Regarding these similarities, the ominous changes of inferior mandibular cortex may be considered as a caution for destructive changes in whole skeleton in CKD and CLF patients. In addition to bone changes, other study also reported different oral microflora between end stage renal disease patient and healthy people (36).

Compared with normal population, the thickness of the inferior mandibular cortex in CKD and CLF patients

is reduced. This is not affected by age and duration of the disease, but is meaningfully related to sex. The liver and kidney disease creates a uniform reduction of mandibular cortex. Panoramic views of patients must be more precisely evaluated to detect any probable changes in cortices and also trabecular patterns. It is also possible to introduce a grading system to predict the extension of changes in bones, according to the amount of changes in mandibular cortex.

5. Conclusion

Inferior mandibular cortex is reduced in CKD and CLF patients comparing with normal population, which is not affected by age and duration of the disease but is meaningfully related to sex. The liver and kidney disease create a uniform reduction of mandibular cortex. Panoramic views of patients must be more precisely evaluated to detect any probable changes in cortices and also trabecular patterns. It is also possible to introduce a grading system to predict the extension of changes in bones, according to the amount of changes in mandibular cortex.

Limitations of the study

Small sample size and simple radiographic technique are of our limitation.

Acknowledgments

The authors thank the Vice-chancellery of Research Shiraz University of Medical Science for supporting this research (Grant# 8895170). This article is based on the thesis by Maryam Faghieh. The authors also thank Dr Vosough of the Dental Research Development Center, of the School of Dentistry for the statistical analysis.

Authors' contribution

JG and AH conducted the research. MF and AH gathered the data. FR, JG and AH and also RD prepared the manuscript. All authors read and signed the final paper.

Conflicts of interest

The authors declare no conflict of interest.

Funding/Support

This article is extracted from undergraduate thesis of Maryam Faghieh. This study was supported by Shiraz University of Medical Sciences (Grant #8895170).

References

1. Lins L, Bittencourt P, Evangelista M, Lins R, Codes L, Cavalcanti A, et al. Oral health profile of cirrhotic patients awaiting liver transplantation in the Brazilian Northeast. *Transplant Proc.* 2011;43:1319-21. doi: 10.1016/j.transproceed.2011.03.063.

2. Guggenheimer J, Mayher D, Eghtesad B. A survey of dental care protocols among US organ transplant centers. *Clin Transplant.* 2005;19:15-8. doi: 10.1111/j.1399-0012.2005.00251.x.
3. Li X, Kolltveit KM, Tronstad L, Olsen I. Systemic diseases caused by oral infection. *Clin Microbiol Rev.* 2000;13:547-58.
4. Seymour G, Ford P, Cullinan M, Leishman S, Yamazaki K. Relationship between periodontal infections and systemic disease. *Clin Microbiol Infect.* 2007;13:3-10. doi: 10.1111/j.1469-0691.2007.01798.x.
5. Yang J, Liu SY, Hossaini-Zadeh M, Pogrel MA. Brain abscess potentially secondary to odontogenic infection: case report. *Oral Surg Oral Med Oral Pathol Oral Radiol* 2014;117:e108-e11. doi: 10.1016/j.oooo.2013.08.011.
6. Martin KJ, González EA. Metabolic bone disease in chronic kidney disease. *J Am Soc Nephrol.* 2007;18:875-85. doi: 10.1681/ASN.2006070771
7. Turkeli M, Dursun H, Albayrak F, Okçu N, Uyanik MH, Uyanik A, et al. Effects of cirrhosis on bone mineral density and bone metabolism. *Eurasian J Med.* 2008;40:18.
8. White SC, Pharoah MJ. *Oral Radiology: Principles and Interpretation.* Elsevier Health Sciences; 2014.
9. Çağlayan F, Dağistan S, Keleş M. The osseous and dental changes of patients with chronic renal failure by CBCT. *Dentomaxillofac Radiol.* 2015;44:20140398. doi: 10.1259/dmfr.20140398
10. Gupta M, Gupta M, Abhishek. Oral conditions in renal disorders and treatment considerations – A review for pediatric dentist. *Saudi Dent J.* 2015;27:113–9. doi: 10.1016/j.sdentj.2014.11.014.
11. Loria I, Albanese C, Giusto M, Galtieri PA, Giannelli V, Lucidi C, et al. Bone disorders in patients with chronic liver disease awaiting liver transplantation. *Transplant Proc.* 2010;42:1191-3. doi: 10.1016/j.transproceed.2010.03.096
12. Bras J, Van Ooij C, Abraham-Inpijn L, Kusen G, Wilmsink J. Radiographic interpretation of the mandibular angular cortex: a diagnostic tool in metabolic bone loss: Part I. Normal state. *Oral Surg Oral Med Oral Pathol.* 1982;53:541-5.
13. Bandeira F, Griz L, Caldas G, Bandeira C, Freese E. From mild to severe primary hyperparathyroidism: the Brazilian experience. *Arq Bras Endocrinol Metabol.* 2006;50:657-63.
14. Watanabe PC, Farman A, Issa JP. Radiographic signals detection of systemic disease. *Orthopantomographic Radiography. Int J Morphol.* 2008;26:915-26.
15. Rani S. Radiological manifestations in patients of chronic renal insufficiency under different modalities of treatment. *J Pharm Biomed Sci.* 2013;26:397-405.
16. Shakibaei Z, Tohidi E, Gholyaf M, Garmrudi B, Garmrudi E. Dentomaxillofacial radiographic changes in a group of Iranian patients with end stage renal disease undergoing hemodialysis. *J Dent Mater Tech.* 2014;3:180-7. doi: 10.22038/jdmt.2014.3349.
17. Patel N, Muñoz SJ. Bone disease in cirrhosis. *Clin Liver Dis (Hoboken).* 2015;6:96-9.
18. Dagistan S, Miloglu O, Caglayan F. Changes in jawbones of male patients with chronic renal failure on digital panoramic radiographs. *Eur J Dent.* 2016;10:64. doi: 10.4103/1305-7456.175699.
19. Horner K, Karayianni K, Mitsea A, Berkas L, Mastoris M, Jacobs R, et al. The mandibular cortex on radiographs as a tool for osteoporosis risk assessment: the OSTEOIDENT Project. *J Clin Densitom.* 2007;10:138-46. doi: 10.1016/j.jocd.2007.02.004.
20. Younossi ZM, Stepanova M, Afendy M, Fang Y, Younossi Y, Mir H, et al. Changes in the prevalence of the most common causes of chronic liver diseases in the United States from 1988 to 2008. *Clin Gastroenterol Hepatol.* 2011;9:524-30. e1. doi: 10.1016/j.cgh.2011.03.020.
21. Sheehy EC, Heaton N, Smith P, Roberts GJ. Dental management of children undergoing liver transplantation. *Pediatr Dent.* 1999;21:272-80.
22. Luxon BA. Bone disorders in chronic liver diseases. *Curr Gastroenterol Rep.* 2011;13:40-8. doi: 10.1007/s11894-010-0166-4.
23. Angulo P, Grandison GA, Fong DG, Keach JC, Lindor KD, Bjornsson E, et al. Bone disease in patients with primary sclerosing cholangitis. *Gastroenterol.* 2011;140:180-8. doi: 10.1053/j.gastro.2010.10.014
24. Guichelaar MM, Schmoll J, Malinchoc M, Hay JE. Fractures and avascular necrosis before and after orthotopic liver transplantation: long-term follow-up and predictive factors. *Hepatology.* 2007;46(4):1198-207. doi: 10.1002/hep.21805
25. Vargas AA, Acevedo JP, Domingo IG, Jiménez RG, Martín JS, Ríos MF, et al. Prevalence and characteristics of bone disease in cirrhotic patients under evaluation for liver transplantation. *Transplant Proc.* 2012;44:1496-8. doi: 10.1016/j.transproceed.2012.05.011.
26. Guañabens N, Cerdá D, Monegal A, Pons F, Caballería L, Peris P, et al. Low bone mass and severity of cholestasis affect fracture risk in patients with primary biliary cirrhosis. *Gastroenterol.* 2010;138:2348-56. doi: 10.1053/j.gastro.2010.02.016.
27. Collier J. Bone disorders in chronic liver disease. *Hepatology.* 2007;46:1271-8. doi: 10.1002/hep.21852
28. Solaymani-Dodaran M, Card TR, Aithal GP, West J. Fracture risk in people with primary biliary cirrhosis: a population-based cohort study. *Gastroenterology.* 2006;131:1752-7. doi: 10.1053/j.gastro.2006.09.012.
29. Proctor R, Kumar N, Stein A, Moles D, Porter S. Oral and dental aspects of chronic renal failure. *J Dent Res.* 2005;84:199-208.
30. Helenius-Hietala J, Meurman JH, Hockerstedt K, Lindqvist C, Isoniemi H. Effect of the aetiology and severity of liver disease on oral health and dental treatment prior to transplantation. *Transplant Int.* 2012;25:158-65. doi: 10.1111/j.1432-2277.2011.01381.x
31. Ardakani FE, Owlia MB, Hesami S, Hosseini P. Digital panoramic radiography as a useful tool for detection of bone loss: a comparative study. *Acta Med Iran.* 2013;51:94.
32. Shakibaei Z, Tohidi E, Gholyaf M, Garmrudi B, Garmrudi E. Dentomaxillofacial radiographic changes in a group of Iranian Patients with end stage renal

- disease undergoing hemodialysis. *The Journal of Dental Materials and Techniques*. 2014(3):180-7. doi:10.22038/jdmt.2014.3349.
33. Queiroz SM, Amorim AG, Andrade AL, Gordón-Núñez MA, Freitas RD, Galvão HC. Influence of dialysis duration and parathyroid hormone on the clinical and radiographic oral conditions of pre-transplant patients with chronic kidney disease. *Brazil J Oral Sci*. 2013;12:125-31.
 34. Monegal A, Navasa M, Guanabens N, Peris P, Pons F, De Osaba MM, et al. Osteoporosis and bone mineral metabolism disorders in cirrhotic patients referred for orthotopic liver transplantation. *Calcif Tissue Int*. 1997;60:148-54.
 35. George J, Ganesh HK, Acharya S, Bandgar TR, Shivane V, Karvat A, et al. Bone mineral density and disorders of mineral metabolism in chronic liver disease. *World J Gastroenterol*. 2009;15:3516-22.
 36. Rezazadeh F, Bazargani A, Roozbeh-Shahroodi J, Pooladi A4, Arasteh P, Zamani K. Comparison of oral *Lactobacillus* and *Streptococcus mutans* between diabetic dialysis patients with non-diabetic dialysis patients and healthy people. *J Renal Inj Prev*. 2016;5:148-52. doi: 10.15171/jrip.2016.31.

Copyright © 2017 The Author(s); Published by Society of Diabetic Nephropathy Prevention. This is an open-access article distributed under the terms of the Creative Commons Attribution License (<http://creativecommons.org/licenses/by/4.0>), which permits unrestricted use, distribution, and reproduction in any medium, provided the original work is properly cited.