

Journal of Nephrothology



The preventive effect of *Berberis vulgaris* extract on contrast-induced acute kidney injury

Shirin Asgharian¹, Zahra Lorigooini¹, Reza Rafieian², Mahmoud Rafieian-Kopaei^{1*}, Soleiman Kheiri³, Hamid Nasri⁴

¹Medical Plants Research Center, Basic Health Sciences Institute, Shahrekord University of Medical Sciences, Shahrekord, Iran

²Student's Research Committee, Shahrekord University of Medical Sciences, Shahrekord, Iran

³Department of Biostatistics and Epidemiology, Faculty of Health, Shahrekord University of Medical Sciences, Shahrekord, Iran

⁴Department of Internal Medicine, Isfahan University of Medical Sciences, Isfahan, Iran

ARTICLE INFO

Article type:
Original Article

Article history:
Received: 10 April 2017
Accepted: 8 August 2017
Published online: 24 August 2017
DOI: 10.15171/jnp.2017.65

Keywords:
Berberis vulgaris
Contrast
Kidney injury
Rat

ABSTRACT

Background: Oxygen free radicals are known as one of the causes of kidney injury. Therefore, *Berberis vulgaris* which has high level of antioxidant activity may be able to prevent this injury by elimination of free radicals.

Objectives: This study was aimed to investigate the protective effect of *B. vulgaris* extract on contrast media-induced nephrotoxicity.

Materials and Methods: To conduct this experimental study, 30 male rats were randomized to three groups; Control, contrast media, and contrast media + *B. vulgaris* extract. After the treatment, histopathological damages to the kidney tissues were comparatively studied.

Results: Tissue damage was greater in the contrast media-treated group than the other two groups ($P < 0.001$). In group treated with *B. vulgaris* extract, the rate of tissue damage decreased significantly ($P < 0.001$).

Conclusions: This study showed the positive effects of *B. vulgaris* on contrast media-induced nephrotoxicity. This inexpensive and non-toxic medicinal plant might be used as an effective agent for people at risk of contrast-induced acute kidney injury (CI-AKI).

Implication for health policy/practice/research/medical education:

The results showed the protective effect of *B. vulgaris* in improving contrast media-induced damage to kidney tissue. Therefore, it might be beneficial in these patients. However, further studies are needed to confirm this and to determine the most suitable doses of *B. vulgaris* extract.

Please cite this paper as: Asgharian S, Lorigooini Z, Rafieian R, Rafieian-Kopaei M, Kheiri S, Nasri H. The preventive effect of *Berberis vulgaris* extract on contrast-induced acute kidney injury. J Nephrothol. 2017;6(4):395-398. DOI: 10.15171/jnp.2017.65.

1. Background

Contrast-induced acute kidney injury (CI-AKI) has been considered as an important factor in induction of acute renal dysfunction (1). Contrast media-induced nephropathy is defined as 25% increase in serum creatinine (Cr) from baseline 3 days after intravenous administration with contrast media (2). CI-AKI has been reported to occur in up to one fourth of patients who undergo coronary interventions (3). Contrast media-induced acute kidney injury (AKI) is the cause of approximately 10% of the impairments of renal function leading to hospitalization (4). After being intravenously

injected, contrast media rapidly circulates in body fluids and is excreted from the body only through glomerular filtration (2,4). If renal function is normal, contrast media is excreted from the body within 24 hours. Meanwhile, there are certain risk factors that make it difficult to excrete contrast media from the body, including renal failure, diabetes mellitus, advanced age, and the characteristics and dosage of contrast media. The main goal should be avoided of contrast media administration to prevent CI-AKI. Recognition and prevention or avoidance of risk factors are also important (1). The CI-AKI pathophysiology has been related to a

*Corresponding author: Prof. Mahmoud Rafieian-Kopaei, Ph.D, Email: rafieian@yahoo.com

complex interplay between tubular and vascular effects. Reduction of medullary blood flow, tubular toxicity, and reactive oxygen species (ROS) generation have been considered as some main risk factors of CI-AKI (3). Following the infusion of contrast media, hypoxemia of the renal medulla, osmotic load, and viscosity the production of ROS via post-ischemic oxidative stress is increased (5,6). Although ROS has been considered as an important mediator of renal damage in CI-AKI, however renal medullary hypoxia is the most important cause of this complication (5-7).

As it is now increasingly believed that the use of medicinal plants become more popular worldwide, the evidence suggests that these plants are unlimited reservoirs of most of drugs (8).

Herbal medicines are a rich source of phenolic compounds with antioxidant activities and most of their beneficial effects have been related to their antioxidant activities (9). On the other hand the status of medicinal plants and their antioxidant effects in reducing kidney injuries have already been confirmed (10,11). *Berberis vulgaris* is one of the medicinal plants with potent antioxidant effect (12-14).

Berberis vulgaris, from family Berberidaceae (15) is grown in most areas of Europe and Asia, particularly in Iran. The medicinal properties this plant especially its fruits, have been previously reported including antioxidant, anticancer, antimicrobial and antiemetic activities (16). *B. vulgaris* is also frequently used to treat kidney diseases in traditional medicine (17).

The fruit of *B. vulgaris* which is very sour and rich in vitamin C is an oblong red berry 7–10 mm long and 3–5 mm broad. They are ripened in late summer or autumn and are usually used as food additive (8).

It seems that the effect of *B. vulgaris* on chronic diseases is due to the presence of alkaloids in this plant. Many important and essential compounds such as bisbenzylisoquinolines, protoberberine and berberine were isolated from *B. vulgaris* (18).

2. Objectives

This study investigated the protective effect of *B. vulgaris* on damage to kidney tissue due to intravenous administration with contrast media.

3. Materials and Methods

3.1. *Berberis vulgaris* preparation and extraction

Berberis vulgaris was provided from reliable sources in Shahrekord, Chaharmahal & Bakhtiari province, southwest Iran, and identified as *B. vulgaris* by a botanist. Then, its herbarium sample was prepared and registered as 419 in the Herbarium Unit of the Medical Plants Research Center of the Shahrekord University of

Medical Sciences (SKUMS). The plant was dried and pulverized using a mill. Five hundred grams of the pulverized plant was macerated and extracted with 70% ethanol in a balloon. The resulting extract was filtered and concentrated in a rotary evaporator 72 hours later. The extract was poured into a plate and incubated at 37°C to dry completely. Then, the dried extract was carved from the plate surface and stored in freezer at -20°C till later use (19).

3.2. Animals

This experimental study was conducted on 30 male Wistar rats weighing 200-250 g. The rats were randomized to three groups; Control group (receiving 10 mg/kg PO normal saline from the first day to the fourth day), contrast media group (receiving 10 mg/kg IV contrast agent on the first day and normal saline from the second day to the fourth day), and *B. vulgaris* group (receiving IV single dose of the contrast agent on the first day and oral 1500 mg/kg of the *B. vulgaris* extract from the second day to the fourth day). The contrast agent used in this experiment was Omnipaque (Hexol) from GE Healthcare Company, Germany.

3.3. The protocol of study

The rats were purchased from Razi Vaccine and Serum Research Institute in Tehran, Iran and transferred to the Animal House of the Medical Plants Research Center of the SKUMS. All rats were maintained under controlled conditions at 24°C and 12 h/12 h light/dark cycle with standard access to food and water. After a one-week adaptation to the animal house environment, the groups underwent their respective treatments according to the protocol of the study. On the fifth day after administration, the rats were sacrificed after they were completely anesthetized and their kidney tissues were removed and formalin-fixed to prepare histopathological samples.

Histopathological lams were prepared by a nephropathologist and qualitatively examined by an optical microscope. The scores of damage to the kidney tissues were 0 (no damage), 1 (1%-19% damage), 2 (20%-49% damage), 3 (40%-69% damage), and 4 (70%-100% damage) (3).

3.4. Ethical issues

The research followed the tenets of the Declaration of Helsinki. This project was approved by Ethics Committee of Shahrekord University of Medical Sciences. All the steps of the experiment were conducted according to the guidelines of the Ethics Committee of the SKUMS and Iranian ethical guidelines for the use of animals.

3.5. Statistical analysis

Data were expressed as mean \pm standard deviation (SD). One-way Analysis of variance (ANOVA) with Tukey's test was used to compare tissue damage in different groups. The level of significance (P) was considered < 0.05 . Data analysis was conducted by Prisma version 5.

4. Results

Figure 1 illustrates the effect of pretreatment with *B. vulgaris* extract on kidney tissue damage in different groups. Intravenous administration with contrast media caused exacerbation of tissue damage compared to normal saline administration in the healthy group ($P < 0.001$). In addition, *B. vulgaris* extract caused significant decrease in contrast media-induced kidney damage compared to contrast media (Figure 1) ($P < 0.001$).

5. Discussion

The current study demonstrated that the contrast agent significantly induced damage to the kidney tissues of the rats, and the rate of kidney damage was higher in the contrast media-treated group compared to the other groups. Besides that, this study confirmed the positive effect of *B. vulgaris* on contrast media-induced kidney tissue such that in group treated with *B. vulgaris* extract to prevent kidney injury, the rate of tissue damage decreased significantly. Contrast medium-induced nephropathy involves multiple factors resulting in hypoxia of the medulla which in turn cause acute tubular necrosis (20). As it was said the pathophysiology of contrast media in induction of AKI is based on medullary ischemia induced by various factors including tubular cell toxicity and formation of free radicals (20). Hence, controlling these mechanisms seems to be effective to control of CI-AKI. Based on the antioxidant activity of many herbs (10,11), they can prevention CI-AKI by reduction of these mechanisms, especially by prevention of free radicals formation.

The positive effects of *B. vulgaris* on in prevention and treatment of the toxicity induced by free radicals in kidney stone disease have been reported, previously (21). Laamech and colleagues' study also have confirmed the protective effect of *B. vulgaris* on lead acetate-induced nephrotoxicity in mice. They found that *B. vulgaris* extract returned renal function parameters and the histopathological changes in the kidney tissue to approximately normal levels. These observations were attributed to the antioxidant property of *B. vulgaris* extract and the effect of this extract in inhibiting lead accumulation (22). A study to investigate the effect of ethanolic *Pimpinella anisum* L. extract on gentamicin-induced nephrotoxicity in rats, reported that the protective effect of this plant was due to its antioxidant activity. In

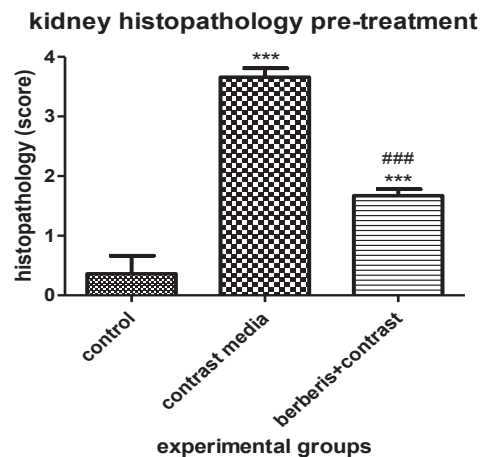


Figure 1. Effect of pretreatment with *Berberis vulgaris* extract on kidney tissue damage in different groups. *** $P < 0.001$ compared to normal saline group. ### $P < 0.001$ compared to other groups.

that study, the levels of biochemical factors were lower and antioxidant capacity was higher in *P. anisum* L. -treated groups than gentamicin-receiving groups (23). Available evidence indicates that antioxidant compounds in *B. vulgaris* such as polyphenols and flavonoids can explain the effects of this plant in relieving tissue damage and improving renal function (24,25). Studies demonstrated the association of nephrotoxicity and oxidative stress (26,27).

6. Conclusions

Our study showed the protective effect of *B. vulgaris* in improving contrast media-induced damage to kidney tissue. However, further studies should be conducted to determine the active doses of *B. vulgaris* extract. Taken together, the use of *B. vulgaris* extract is an inexpensive

Authors' contribution

MRK and SA; designed, conducted, supervised and analyzed the research and prepared the first draft of article. ZLG and RF; participated in the performance of the research and collected the data. HN, handled the pathology of the kidneys. SK analyzed the pathology data. MRK; prepared the paper. All authors read and signed the final paper.

Conflicts of interest

The authors declared no competing interests.

Funding/Support

The study was supported by NIMAD (Grant # 943726).

References

1. Tepel M, Aspelin P, Lameire N. Contrast-induced

- nephropathy. *Circulation*. 2006;113(14):1799-806.
2. Maliborski A, Żukowski P, Nowicki G, Boguslawska R. Contrast-induced nephropathy—a review of current literature and guidelines. *Medical Science Monitor*. 2011;17(9):RA199-RA204.
 3. Nasri H, Tavakoli M, Ahmadi A, Baradaran A, Nematbakhsh M, Rafeian-Kopaei M. Ameliorative effect of melatonin against contrast media induced renal tubular cell injury. *Pak J Med Sci*. 2014;30(2):261-5.
 4. McDonald RJ, McDonald JS, Bida JP, Carter RE, Fleming CJ, Misra S, et al. Intravenous contrast material-induced nephropathy: causal or coincident phenomenon? *Radiology*. 2013;267(1):106-18.
 5. Sanadgol H, Abdani S, Tabatabaiee P, Mohammadi M. Protective effect of high dose short term statin therapy with normal saline in prevention of contrast-induced nephropathy among iodixanol-receiving patients. *J Renal Inj Prev*. 2012;1(1):43.
 6. Kwok C, Pang C, Yeong J, Loke Y. Measures used to treat contrast-induced nephropathy: overview of reviews. *Br J Radiol*. 2013;86(1021):20120272. doi: 10.1259/bjr.20120272.
 7. Mehran R, Nikolsky E. Contrast-induced nephropathy: definition, epidemiology, and patients at risk. *Kidney Int Suppl*. 2006;(100):S11-5.
 8. El-Wahab AEA, Ghareeb DA, Sarhan EE, Abu-Serie MM, El Demellawy MA. In vitro biological assessment of *Berberis vulgaris* and its active constituent, berberine: antioxidants, anti-acetylcholinesterase, anti-diabetic and anticancer effects. *BMC Complement Altern Med*. 2013;13:218. doi: 10.1186/1472-6882-13-218.
 9. Shirzad H, Tajji F, Rafeian-Kopaei M. Correlation between antioxidant activity of garlic extracts and WEHI-164 fibrosarcoma tumor growth in BALB/c mice. *J Med Food*. 2011;14(9):969-74.
 10. Rafeian-Kopaei M, Baradaran A, Rafeian M. Plants antioxidants: From laboratory to clinic. *J Nephrothol*. 2013;2(2):152-3. doi: 10.12860/JNP.2013.26.
 11. Rafeian-Kopaei M. Medicinal plants and the human needs. *J HerbMed Pharmacol*. 2012;1(1):1–2.
 12. Nickavar B, Abolhasani FA. Screening of antioxidant properties of seven Umbelliferae fruits from Iran. *Pak J Pharm Sci*. 2009;22(1):30-5.
 13. Dastmalchi K, Dorman HD, Koşar M, Hiltunen R. Chemical composition and in vitro antioxidant evaluation of a water-soluble Moldavian balm (*Dracocephalum moldavica* L.) extract. *LWT-Food Science and Technology*. 2007;40(2):239-48.
 14. Hanachi P, Golkho S. Using HPLC to determination the composition and antioxidant activity of *Berberis vulgaris*. *Eur J Sci Res*. 2009;29(1):47-54.
 15. Zargari A. *Medicinal Plants*. Tehran: Tehran University Publications.;1995.
 16. Hoshyar R, Mahboob Z, Zarban A. The antioxidant and chemical properties of *Berberis vulgaris* and its cytotoxic effect on human breast carcinoma cells. *Cytotechnology*. 2016;68(4):1207-13.
 17. Fatehi M, Saleh TM, Fatehi-Hassanabad Z, Farrokhfal K, Jafarzadeh M, Davodi S. A pharmacological study on *Berberis vulgaris* fruit extract. *J Ethnopharmacol*. 2005;102(1):46-52.
 18. Ivanovska N, Philipov S. Study on the anti-inflammatory action of *Berberis vulgaris* root extract, alkaloid fractions and pure alkaloids. *Int J Immunopharmacol*. 1996;18(10):553-61.
 19. Heidarian E, Rafeian-Kopaei M. Protective effect of artichoke (*Cynara scolymus*) leaf extract against lead toxicity in rat. *Pharm Biol*. 2013;51(9):1104-9. doi: 10.3109/13880209.2013.777931.
 20. Wong PCY, Li Z, Guo J, Zhang A. Pathophysiology of contrast-induced nephropathy. *Int J Cardiol*. 2012;158(2):186-92.
 21. Jyothilakshmi V, Thellamudhu G, Chinta R, Alok K, Anil K, Debadatta N, et al. Beneficial antioxidative effect of the homeopathic preparation of *Berberis vulgaris* in alleviating oxidative stress in experimental urolithiasis. *Forsch Komplementmed*. 2014;21(1):7-12.
 22. Laamech J, El-Hilaly J, Fetoui H, Chtourou Y, Tahraoui A, Lyoussi B. Nephroprotective effects of *Berberis vulgaris* L. total extract on lead acetate-induced toxicity in mice. *Indian J Pharm Sci*. 2016;78(3):326-33.
 23. Changizi-Ashtiyani S, Seddigh A, Najafi H, Hossaini N, Avan A, Akbary A, et al. Pimpinella anisum L. ethanolic extract ameliorates the gentamicin-induced nephrotoxicity in rats. *Nephrology*. 2017;22(2):133-8.
 24. Abdel-Raheem IT, Abdel-Ghany AA, Mohamed GA. Protective effect of quercetin against gentamicin-induced nephrotoxicity in rats. *Biol Pharm Bull*. 2009;32(1):61-7.
 25. Otunctemur A, Ozbek E, Dursun M, Sahin S, Besiroglu H, Ozsoy OD, et al. Protective effect of hydrogen sulfide on gentamicin-induced renal injury. *Ren Fail*. 2014;36(6):925-31.
 26. Cuzzocrea S, Mazzon E, Dugo L, Serraino I, Di Paola R, Britti D, et al. A role for superoxide in gentamicin-mediated nephropathy in rats. *Eur J Pharmacol*. 2002;450(1):67-76.
 27. Atessahin A, Yilmaz S, Karahan I, Ceribasi AO, Karaoglu A. Effects of lycopene against cisplatin-induced nephrotoxicity and oxidative stress in rats. *Toxicology*. 2005;212(2):116-23.