

# Journal of Nephropathology



## Appendix graft as a ureter substitution in recurrent ureter stenosis in horse-shoe kidney; a case report

Ali Taghizadeh Afshari<sup>1</sup>, Rohollah Valizadeh<sup>2</sup>, Saman Farshid<sup>1\*</sup>

<sup>1</sup>Nephrology and Kidney Transplant Research Center, Urmia University of Medical Sciences, Urmia, Iran

<sup>2</sup>Student Research Committee, Urmia University of Medical Sciences, Urmia, Iran and PhD student in Epidemiology, Department of Epidemiology, Student Research Committee, Iran University of Medical Sciences, Tehran, Iran

### ARTICLE INFO

*Article type:*  
Case Report

*Article history:*  
Received: 10 July 2017  
Accepted: 14 October 2017  
Published online: 2 November 2017  
DOI: 10.15171/jnp.2018.23

*Keywords:*  
Appendix  
Ureter Stenosis  
Horse-Shoe kidney  
Graft

### ABSTRACT

**Background:** A horseshoe kidney is the most common renal fusion anomaly and occurs in 0.2% to 0.3% of the population. Horseshoe kidneys are fused by the formation of an isthmus between the lower poles of the left and right kidneys during development. The insertion of the ureter in the renal pelvis is displaced super-laterally, probably as the result of incomplete renal rotation, and is associated with a significant rate of ureteropelvic junction (UPJ) obstruction.

**Case Presentation:** We report a patient with single kidney at right side with obstruction in upper ureter. Before the surgery our plan was transureteroureterostomy according to failure of previous surgeries, dismembered pyeloplasty and ureterocalicostomy, but after mobilizing the proximal ureter we noticed that transureteroureterostomy was impossible because of short fibrotic ureter. Other choices such as Boari flap technique with psoas hitch is impossible because of small fibrotic bladder, so we decided to use appendix as ureter substitute.

**Conclusions:** According to our experience and previous studies, we can use appendix as a ureter substitution in refractory proximal and middle ureter stenosis, but in our case we anatomized proximal ureter to appendix instead of anastomosis of pelvic to appendix.

### *Implication for health policy/practice/research/medical education:*

Given the acceptable results of appendix as a ureter substitution in refractory proximal and middle ureter stenosis, it can be used instead of anastomosis of pelvic in such a situation.

*Please cite this paper as:* Taghizadeh Afshari A, Valizadeh R, Farshid S. Appendix graft as a ureter substitution in recurrent ureter stenosis in horse-shoe kidney; a case report. J Nephropathol. 2018;7(2):98-100. DOI: 10.15171/jnp.2018.23.

### 1. Background

A horseshoe kidney is the most common renal fusion anomaly and occurs in 0.2% to 0.3% of the population (1). Horseshoe kidneys are fused by the formation of an isthmus between the lower poles of the left and right kidneys during development. The insertion of the ureter in the renal pelvis is displaced super-laterally, probably as the result of incomplete renal rotation, and is associated with a significant rate of ureteropelvic junction (UPJ) obstruction (2).

Ureteric injury is a potential complication of any open abdominal surgery, laparoscopy and ureteroscopy. In urology, the most common procedure resulting in ureteral injuries is avulsion injury after ureteroscopy.

However, with increasing knowledge and experience minimally invasive endoscopic procedures have become safe (3). Melnikoff explained how to use of the appendix as a useful method in ureteric reconstruction in the last century (4). From that time until now multiple case reports and small case series have been published on appendicular interposition (2,5). Restricted availability after appendectomy, post-inflammatory changes and fibrosis, missing length and a short mesoappendix may limit the use of the appendix (6,7). Ureteric reconstruction offers patients the best chance of long-term patency, but ureteroneocystostomy with Boari flap, ureteroureterostomy, ileal interposition and autotransplant may not always be feasible.

\*Corresponding author: Saman Farshid, Email: safarshid22@gmail.com

## 2. Case Presentation

The patient was a 14-year-old boy with horse-shoe kidney, right side UPJO and atrophic left kidney diagnosis was done with hematuria after abdominal trauma 4 years ago. In review of familial history of the patient, both of mother and father had nephrolithiasis and his sister suffered from end-stage renal failure (ESRD). He referred to our clinic for recurrent right ureteral stricture stenosis after dismembered pyeloplasty and ureterocalicostomy, and frequent stent insertion. According to imaging studies proximal ureter stenosis observed in this patient. Our positive findings in examination included right flank scar and left testis atrophy with laboratory data serum creatinine; 1.1 mg/dL, Na; 143 mEq/L, K; 3.7 mEq/L, calcium; 9.8 mg/dL and urine culture was negative. The results of imaging were including renal ultrasonography that showed right kidney with severe hydronephrosis (Figure 1), length was 13.4cm, parenchyma was around 2 cm and the length of left small kidney was 4 cm. Antegrade pyelography showed stenosis of proximal ureter (Figure 2). CT scan showed severe right renal hydronephrosis and atrophic left kidney, CT angiography showed two arteries originated from aorta for right kidney. Dimercaptosuccinic acid (DMSA) scan showed right kidney hydronephrosis and left kidney without function. After all diagnostic examinations, we decided to preform transureteroureterostomy of proximal right ureter but because of short proximal ureter of the donor, we changed our surgical plan. After dividing the two-thirds of distal ureter and excision of appendix with good vascular base from cecum, we spatulated the proximal ureter from lateral and then we anastomosed proximal ureter to appendix base by 4-0 vicryl. Then we inserted 4.8 Fr stent in appendix and pushed it up to collecting system and put the other end in the bladder. Finally, we anastomosed appendix tip to bladder dome with 4-0 vicryl by Lich-Gregoir technique. We illustrated shape and position of appendix after anastomosis as a photo (Figure 4). We removed drain tube in second postoperative day and urethra catheter after 5 days, ureteral stent was removed after 1 month. Imaging studies including EC Scan were done 1 month and 6 month after stent removal results were ruled out the obstruction.

## 3. Discussion

The horseshoe kidney is the most common of all renal fusion anomalies. Horse shoe kidney occurs in 0.25% of the population, or about 1 in 400 persons (1). Previously, up to one-third of individuals with horseshoe kidney had hydronephrosis secondary to UPJ obstruction (8). In the modern era, horseshoe kidneys are frequently discovered incidentally, and their

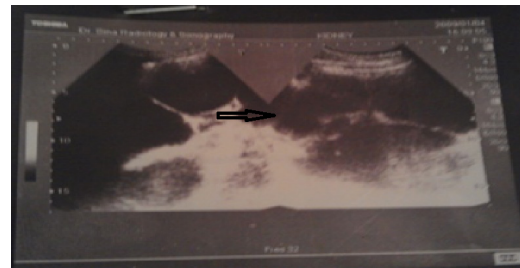

Figure 1. Ultrasonography of patient with cystic right kidney.

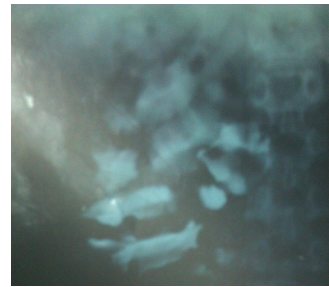


Figure 2. Antegrade pyelography of patient with stenosis of proximal ureter.

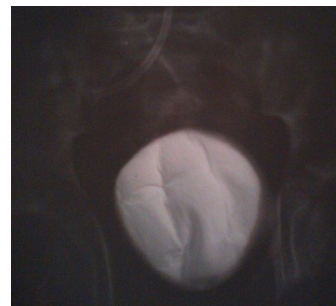

Figure 3. Retrograde cystography of patient that with two arteries originated from aorta.

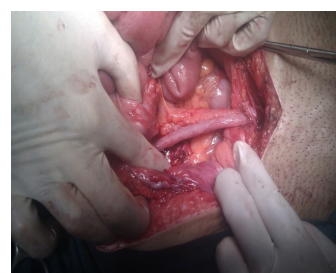

Figure 4. Appendix position in horseshoe kidney.

apparent hydronephrosis often shows a non-obstructed pattern on radionuclide scanning (9). The indications for curing obstruction in horseshoe related UPJO are the same as other UPJO conditions, impairment of overall renal function or progressive impairment of ipsilateral function, development of stones or infection, or, rarely, causal hypertension. Gold standard of surgery for UPJO is dismembered pyeloplasty surgery, however less aggressive endourologic procedures may have a role in these patients (10). Dismembered pyeloplasty is not well suited to UPJ obstruction associated with lengthy or

multiple proximal ureteral strictures or to patients in whom the UPJ obstruction is associated with a small, relatively inaccessible intrarenal pelvis. Ureterocalicostomy may be used as a primary reconstructive procedure whenever a UPJ obstruction or proximal ureteral stricture is associated with a relatively small intrarenal pelvis. Furthermore, ureterocalicostomy is a well-accepted salvage technique for the failed pyeloplasty (11). Open transureteroureterostomy for treatment of ureteral stenosis is effective while ureteral length is short for anastomosis to the bladder and it is considered as an absolute contraindication of the donor of ureter. The use of other tissue for anastomosis is defined for some situations in which a defect cannot be repaired by other procedures or the bladder is not suitable for injured ureter. Additionally, the use of appendix and fallopian tube are unreliable ureteral substitutes in some cases (2).

#### 4. Conclusions

In conclusion, we believe that this graft is a good option for reconfiguration of the ureter stenosis when condition is acceptable. It is an easy and safe procedure that provides acceptable therapeutic results with a good urinary flow.

#### Authors' contribution

Primary draft was done by RV, ATA and SF. RV participated in the case discussion and assisted the patient. The manuscript was edited by SF. All authors read the final version.

#### Conflicts of interest

The authors declare no conflict of interest.

#### Ethical considerations

Ethical issues (including plagiarism, data fabrication, double publication) have been completely observed by the authors. Informed consent was obtained from the patient regarding this case report.

#### Funding/Support

None to be declared.

#### References

1. Glenn JF. Analysis of 51 patients with horseshoe kidney. *N Engl J Med.* 1959; 261:684-7. doi: 10.1056/NEJM195910012611402.
2. Deyl RT, Averbek MA, Almeida GL, Pioner GT, Souto CA. Appendix interposition for total left ureteral reconstruction. *J Pediatr Urol.* 2009;5(3):237-9. doi: 10.1016/j.jpuro.2008.11.010.
3. Selzman AA, Spirnak JP. Iatrogenic ureteral injuries: a 20-year experience in treating 165 injuries. *J Urol.* 1996; 155(3):878-81. doi: 10.1016/S0022-5347(01)66332-8.
4. Melnikoff AE. Sur le remplacement de l'uretere par anse isolee de l'intestine grele. *Rev Clin Urol* 1912;1:601.
5. Weinberg RW. Appendix ureteroplasty. *Br J urol* 1976;48:234
6. Die Goyanes A, Garcia Villanueva A, Lavalle Echavarría JA, Cabannas Navarro L. Replacement of the left ureter by autograft of the vermiform appendix. *Br J Surg.* 1983;70(7):442-3.
7. Jang TL, Matschke HM, Rubenstein JN, Gonzalez CM. Pyeloureterostomy with interposition of the appendix. *J Urol.* 2002;168(5):2106-7. doi: 10.1097/01.ju.0000034257.61988.cf.
8. Ding J, Huang Y, Gu S, Chen Y, Peng J, Bai Q, et al. Flexible ureteroscopic management of horseshoe kidney renal calculi. *Int Braz J Urol.* 2015; 41(4): 683-89. doi:10.1590/S1677-5538.IBJU.2014.0086.
9. Huber D, Griffin A, Niesche J, Frawley J, Gray L. Aortic aneurysm surgery in the presence of a horseshoe kidney. *Aust N Z J Surg.* 1990;60(12):963-6. doi:10.1111/j.1445-2197.1990.tb07514.x
10. McDougal WS, Kavoussi LR, Wein AJ, Novick AC, Partin AW. *Campbell-Walsh Urology Tenth Edition Review*: Elsevier; 2011. In: *Campbell Walsh Urology: Pediatric Urology*. 1st ed. Elsevier; 2011.
11. Ross JH, Strem SB, Novick AC, Kay R, Montie J. Ureterocalicostomy for reconstruction of complicated pelviureteric junction obstruction. *Br J Urol.* 1990; 65(4):322-5.

**Copyright** © 2018 The Author(s); Published by Society of Diabetic Nephropathy Prevention. This is an open-access article distributed under the terms of the Creative Commons Attribution License (<http://creativecommons.org/licenses/by/4.0>), which permits unrestricted use, distribution, and reproduction in any medium, provided the original work is properly cited.