

Journal of Nephropathology



Painful angiomyxoid tumor in a failed renal allograft presenting as post-transplant lymphoproliferative disorder

Paulette Cutruzzula Dreher^{1*}, Jessica M. Fazendin², Kelly Lurz^{1,2}, Daniel C. Edwards¹, Stephen Guy¹, Melanie Amster¹

¹Department of Urology, Hahnemann University Hospital, Philadelphia, PA, USA

²Department of General Surgery, Drexel University College of Medicine, Philadelphia, PA, USA

³Department of Transplant Surgery, Drexel University College of Medicine, Philadelphia, PA, USA

ARTICLE INFO

Article type:
Case Report

Article history:
Received: 6 May 2018
Accepted: 27 July 2019
Published online: 10 September 2019

Keywords:
Angiomyxoid tumor,
Renal transplant,
Post-transplant lymphoproliferative
disease,
Malakoplakia

ABSTRACT

Introduction: There exist few reports of de novo tumors involving an allograft kidney, and to the best of our knowledge there are only two previous reports of angiomyxoma

Case Presentation: A 53-year-old Caucasian male with end-stage renal disease (ESRD) on hemodialysis (HD) secondary to malakoplakia with three failed prior renal transplants presented for repeat transplant evaluation. Imaging demonstrated a mass of the transplanted kidney suggestive of post-transplant lymphoproliferative disease (PTLPD). A biopsy was obtained revealing a predominance of myxoid material. The patient became increasingly symptomatic from the mass and underwent a palliative right transplant nephrectomy. Final pathology revealed angiomyxoid tumor.

Conclusions: Angiomyxomas are asymptomatic, appear as PTLD on imaging and should be considered in the differential diagnosis of masses occurring in renal transplant allografts.

Implication for health policy/practice/research/medical education:

Allograft kidney transplant patients presenting with post-transplant lymphoproliferative disease on imaging should be considered in differential diagnosis of rare masses occurring de novo in renal transplant patients.

Please cite this paper as: Dreher PC, Fazendin JM, Lurz K, Edwards DC, Guy S, Amster M. Painful angiomyxoid tumor in a failed renal allograft presenting as post-transplant lymphoproliferative disorder. J Nephropathol. 2020;9(2):e20. DOI: 10.34172/jnp.2020.20.

Introduction

De novo tumors involving renal allografts are extremely rare. However, when they occur they are largely malignant and arise from the native kidneys (1). Angiomyxoid tumors are an uncommon entity historically discovered in the female pelvis and perineum. We present the rare entity of a de novo angiomyxoma in a renal allograft seven years after transplant failure.

Case Presentation

A 53-year-old Caucasian male with history of malakoplakia and subsequent end-stage renal disease (ESRD) on hemodialysis (HD) since age 16 presented to our institution for transplant evaluation. He had undergone three prior renal transplants (autologous,

living unrelated donor, and living related), which subsequently failed due to thrombosis, rapid rejection, and glomerulonephropathy, respectively. Computed tomography (CT) revealed an 8.5 × 5.0 × 12 cm soft tissue density surrounding the transplant kidney consistent with post-transplant lymphoproliferative disease (PTLPD). A CT-guided biopsy of the mass revealed mature fat, chronic inflammation, and few plump spindle cells in background of abundant myxoid material.

One month later, the patient presented with complaints of severe right lower quadrant pain. Ultrasound revealed no obvious mass in the allograft. CT demonstrated interval increase in the size of the mass in the AP diameter, now 6.9cm. Due to intractable pain, the patient underwent palliative transplant nephrectomy. Subsequently, his pain

*Corresponding author: Paulette Cutruzzula Dreher,
Email: paulettecuc@pcom.edu

resolved and he remains on HD with routine surveillance imaging of his pelvis.

Gross examination of the specimen revealed an irregular, ill-defined mass attached to the hilum of the kidney that measured 11.5 × 6 × 4.8 cm. No lymphadenopathy was appreciated. The surface of the mass appeared yellow-tan in color with nodular focal areas of hemorrhage. The cut surface showed nodular myxoid and fibro-fatty tissue partially replacing the kidney and extending out and around the kidney (Figure 1). Microscopic examination revealed adipose tissue with nodular myxoid, prominent thick-wall vascular channels, spindle cells, fibrosis, and scattered inflammatory cells with clusters of small and mature lymphocytes (Figure 1). Immunohistochemical stains were negative for MDM2, CDK4, AFB, GMS, and PAS. Fluorescent in-situ hybridization cytology stains was also negative. Findings were consistent with the diagnosis de novo angiomyxoid tumor of the renal allograft arising from the adipose tissue of the allograft kidney.

Discussion

Angiomyxoid tumors are asymptomatic, slow-growing masses that displace adjacent structures rather than invade, and lack metastatic potential (2). They are characterized by the presence of prominent myxoid and vascular components and most frequently occur in the adult female pelvic floor and perineum. Aggressive variants have been reported to occur in the cervix, scrotum, inguinal region, and male pelvis (3). Diagnosis of these tumors is usually delayed due to their asymptomatic nature, and they are often incidentally found on imaging. Radiographic appearance on CT scan usually reveals a hypo-attenuating mass with areas of enhancement that is classically described as a “swirl” pattern. Most reported cases of angiomyxoid tumor suggest imaging is consistent

with the diagnosis of PTLD.

Complete surgical resection is the gold standard of treatment, but local recurrence rates can range from 35%-72% despite negative margins (4,5). On gross exam the tumors have been noted to be encapsulated, located in the peri-pelvic tissue, and with a cut surface revealing a gelatinous tumor with foci of hemorrhage (3). Microscopic identification of angiomyxoma is based on the presence of spindle and stellate-shaped cells, and myxoid stroma with multiple vascular channels (2,3). Immunohistochemical stains and cytology on our patient were positive for CD34, but were otherwise unremarkable. Traditionally, this tumor stains positive for vimentin, CD34, and negative for S100, as well as being estrogen receptor and progesterone receptor positive (5). In the case reports occurring in allograft kidney transplants, each case reported positive vimentin and CD34, with one case positive for S100 (2,3).

Unique to this case study is the presence of associated pain as well as the diagnosis of malakoplakia. Current literature reveals no explanation for the patient’s intractable pain or a connection between the underlying diagnosis of malakoplakia and the development of angiomyxoma.

As angiomyxomas are generally asymptomatic with a tendency for local recurrence, radiographic surveillance imaging is required (5). While our patient’s tumor was not defined as aggressive, a recent surveillance CT scan (3 months status post right transplant nephrectomy) revealed a small soft tissue density (2.8 × 3.0 cm) in the iliac fossa that cannot exclude mass residual or recurrence of disease. Patient is being followed closely with interval imaging.

Conclusions

Angiomyxoma is a rare lesion that may develop in a transplanted kidney and should be considered in the

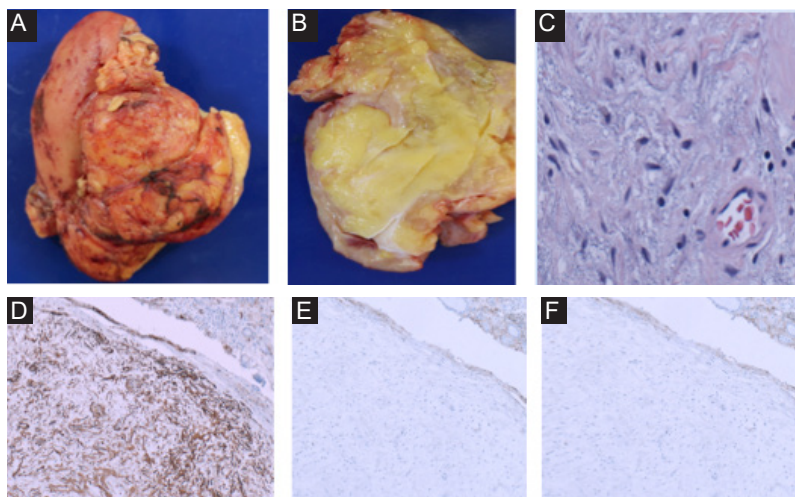


Figure 1. (A) Gross specimen, (B) cut edge gross specimen, (C) He 400x, (D) CD34, (E) S100, (F) SMA 40.

differential diagnosis in patients presenting with clinical symptoms and radiological imaging consistent with PTLD. Treatment of these tumors is surgical excision with radiological surveillance as these tumors have a tendency to locally recur.

Authors' contribution

PCD; manuscript composition, literature review. JMF; manuscript composition. KL; literature review. DCE; manuscript composition. MA; senior author. SG; senior author. All authors read and signed the final manuscript.

Conflicts of interest

None.

Ethical considerations

Ethical issues including plagiarism, double publication, and redundancy have been completely observed by the authors. The patient gave his consent to publish as a case report.

Funding/Support

No funding.

References

1. Ghasemian SR, Guleria AS, Light JA, Sasaki TM. Multicentric renal cell carcinoma in a transplanted kidney. *Transplantation*. 1997;64(8):1205-6.
2. Gorski U, Naranje P, Rathi M, Nada R, Khadelwal N. Aggressive angiomyxoma of transplanted kidney mimicking posttransplant lymphoproliferative disorder. *Saudi J Kidney Dis Transpl*. 2017;28(2):425-427. doi: 10.4103/1319-2442.202778.
3. Gondo T, Takahashi M, Hoshii Y, Iwata T, Kawshiwagi T, Ishihara T. Angiomyxoid tumor in the renal peripelvic tissues with features of aggressive angiomyxoma. *J Clin Pathol*. 1995;48(1):82-3. doi: 10.1136/jcp.48.1.82.
4. Chan YM, Hon E, Ngai SW, Ng TY, Wong LC. Aggressive angiomyxoma in females: is radical resection the only option? *Acta Obstet Gynecol Scand*. 2000;79(3):216-20.
5. Mathieson A, Chandrakanth S, Yousef G, Wadden P. Aggressive angiomyxoma of the pelvis: a case report. *Can J Surg*. 2007;50(3):228-9.

Copyright © 2020 The Author(s); Published by Society of Diabetic Nephropathy Prevention. This is an open-access article distributed under the terms of the Creative Commons Attribution License (<http://creativecommons.org/licenses/by/4.0>), which permits unrestricted use, distribution, and reproduction in any medium, provided the original work is properly cited.